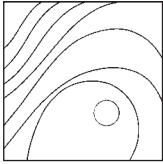


# Minimally Invasive Management of Implant-Supported Rehabilitation in the Posterior Maxilla, Part II. Surgical Techniques and Decision Tree



Claudio Stacchi, DDS, MSc<sup>1</sup>  
 Sergio Spinato, DDS, PhD<sup>2</sup>/Teresa Lombardi, DDS<sup>3</sup>  
 Fabio Bernardello, MD, DDS<sup>4</sup>/Carlo Bertoldi, MD, DDS<sup>2</sup>  
 Davide Zaffe, MBiolSci<sup>5</sup>/Myron Nevins, DDS<sup>6</sup>

*Insufficient crestal bone is a common feature encountered in the edentulous posterior maxilla due to atrophy of the alveolar ridge and maxillary sinus pneumatization. Numerous surgical techniques, grafting materials, and timing protocols have been proposed for implant-supported rehabilitation of posterior maxillae with limited bone height. In the majority of potential implant sites, residual bone height is less than 8 mm and the clinician has to select either a lateral or transcresal sinus-elevation technique or placing short implants as the correct surgical option. Nevertheless, guidelines for selecting the best option remains mostly based on the personal experience and skills of the surgeon. The role of sinus anatomy in healing and graft remodeling after sinus floor augmentation is crucial. In addition to the evaluation of residual bone height, the clinician should consider that histologic and clinical outcomes are also influenced by the buccal-palatal bone wall distance. Therefore, three main clinical scenarios may be identified and treated with either a lateral or transcresal sinus-elevation technique or short implants. This article introduces a new decision tree for a minimally invasive approach based on current evidence to help the clinician safely and predictably manage implant-supported treatment of the atrophic posterior maxilla.* Int J Periodontics Restorative Dent 2020;40:e95–e102. doi: 10.11607/prd.4498

The posterior maxilla is a challenging area for implant-supported rehabilitation, and important preliminary considerations are necessary to select the most appropriate treatment options. The analysis of intermaxillary relationships should determine if atrophy is related mainly to sinus pneumatization or to ridge resorption and, consequently, if vertical ridge augmentation procedures are required (alone or in combination with sinus lift) to obtain an acceptable prosthetic rehabilitation.<sup>1</sup> Edentulous ridge morphology has also to be evaluated in terms of horizontal width: Buccal and palatal bone around the planned implant should have a minimum thickness of 1 to 1.5 mm to ensure marginal bone stability and long-term success.<sup>2</sup>

Once these preliminary assessments have been made, the residual crest has to be evaluated in terms of height and bone quality. If the sinus floor is located > 8 mm from the alveolar crest, a standard-length implant may be placed routinely in the residual bone without additional augmentation procedures.<sup>3</sup>

However, in the majority of potential implant sites, residual bone height is less than 8 mm,<sup>4</sup> and the clinician has to select the best treatment approach among various surgical options (short implants or transcresal or lateral sinus-elevation techniques).

<sup>1</sup>Department of Medical, Surgical and Health Sciences, University of Trieste, Trieste, Italy.

<sup>2</sup>Department of Surgery, Medicine, Dentistry and Morphological Sciences with Transplant Surgery, Oncology and Regenerative Medicine Relevance, University of Modena and Reggio Emilia, Modena, Italy.

<sup>3</sup>Department of Health Sciences, Magna Graecia University, Catanzaro, Italy.

<sup>4</sup>Private practice, Legnago (VR), Italy.

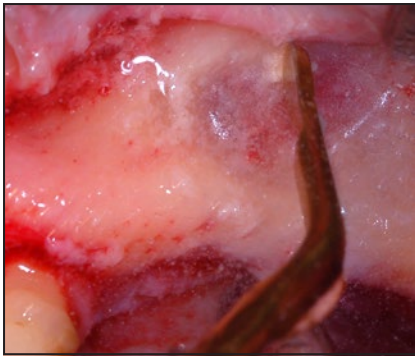
<sup>5</sup>Department of Biomedical, Metabolic and Neural Sciences, University of Modena and Reggio Emilia, Modena, Italy.

<sup>6</sup>Department of Oral Medicine, Infection and Immunity, Division of Periodontology, Harvard School of Dental Medicine, Boston, Massachusetts, USA.

Correspondence to: Dr Claudio Stacchi, Department of Medical, Surgical and Health Sciences, University of Trieste, Corso Italia, 121, 34170 Gorizia, Italy.  
 Email: claudio@stacchi.it

Submitted June 7, 2019; accepted July 9, 2019.

©2020 by Quintessence Publishing Co Inc.



**Fig 1** Reduction of cortical thickness before window outlining represents the safest procedure in order to minimize the risk of membrane perforation during sinus floor elevation with a lateral approach.

In this article, after a brief narrative review of the current evidence on sinus augmentation techniques and short implants, the authors introduce a novel decision tree for rational planning of minimally invasive implant-supported rehabilitations in the atrophic posterior maxilla.

## Surgical Techniques

### *Sinus Floor Elevation with Lateral Approach*

Sinus floor elevation with lateral access has been widely studied and consistently described as a safe and highly predictable treatment.<sup>5</sup> This surgical procedure involves elevation of the sinus membrane through a window outlined on the lateral sinus wall to create sufficient vertical space for bone augmentation in preparation for implant placement. Window dimensions were reported

to significantly influence both maturation and consolidation of the graft. Specifically, bone healing could be hindered when a large window is opened, due to a decrease in neoangiogenesis and cellular supply.<sup>6</sup> The reduced size of the window was demonstrated to affect neither the safety of the procedure nor the surgical time but did seem to reduce postoperative discomfort.<sup>7</sup>

Sinus membrane perforation is the most common intraoperative complication when performing sinus augmentation and was identified as a significant risk factor leading to potential postoperative complications and graft failure.<sup>8</sup> Membrane perforation is strongly influenced not only by various anatomical factors (risk increases in presence of a narrow sinus cavity as well as maxillary sinus septa and membrane thickness < 1 mm)<sup>8</sup> but also by surgical technique. Use of piezoelectric devices significantly reduces the risk of perforation when compared to rotary instruments.<sup>9</sup> Reducing the cortical thickness before window outlining seems to be the safest procedure in order to preserve membrane integrity<sup>10,11</sup> (Fig 1).

After lateral window opening, adequate detachment of the sinus membrane, with consequent exposure of sinus floor and buccal and palatal bony walls, is crucial for fast and predictable graft vascularization and colonization by mesenchymal osteoprogenitor cells, the main biologic bases for new bone formation. Membrane elevation from the palatal sinus wall is particularly important for two main reasons. First, the posterior lateral nasal artery located

on the medial sinus wall can contribute as an additional source of blood supply to the graft.<sup>12</sup> Second, careful and complete detachment reduces membrane tension and therefore risk of perforation.

The role of sinus anatomy in conditioning, healing, and graft remodeling after lateral sinus floor augmentation is crucial. A recent study evaluated the influence of buccal-palatal bone wall distance on sinus augmentation histologic outcomes and showed that the percentage of vital bone formation is inversely proportional to this distance.<sup>13</sup> The narrower the sinus cavity, the shorter the maturation time required to achieve a suitable amount of new bone.

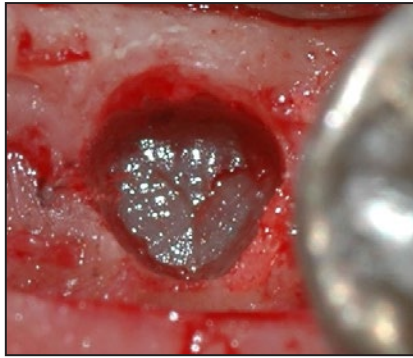
### *Sinus Floor Elevation with Transcrestal Approach*

Sinus floor elevation with transcrestal approach (tSFE) was introduced by Summers<sup>14</sup> and consisted of a minimally invasive grafting procedure using osteotomes to break through and compact the residual alveolar ridge in order to reduce patient morbidity and preserve integrity of sinus bone walls, the most important source of blood and osteogenic cells. Many techniques have since been developed. Depending on the surgical protocol, sinus floor opening may be performed using osteotomes,<sup>15</sup> specially designed burs,<sup>16</sup> or ultrasonic devices<sup>17</sup> (Fig 2). Sinus membrane elevation may be performed either by gradual insertion of well-hydrated biomaterial or by using hydrodynamic pressure

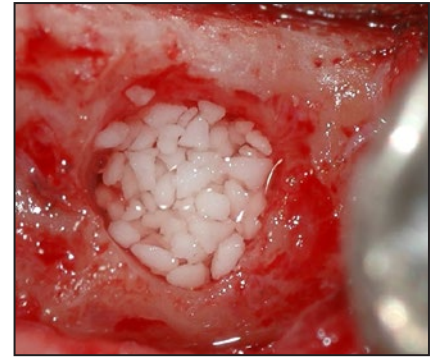
(Fig 3). There is no scientific evidence demonstrating the superiority of any one of these techniques, and comparative clinical trials are therefore needed.

While tSFE with Summers's technique can safely elevate the membrane a few millimeters, recent technical improvements allow more significant augmentations and can be used even in the presence of minimal vertical amounts of native bone.<sup>18</sup>

However, the "blindness" of the tSFE is considered to be its main drawback, due to the difficulty in detecting small perforations and, most importantly, in controlling and guiding sinus membrane elevation. In fact, both progressive increments of biomaterial and hydrodynamic pressure detach the sinus membrane from the sinus floor and walls following the path of least resistance. The consequence is that an adequate membrane elevation (exposing both lateral and medial sinus walls) is a predictable outcome only for sinus cavities with a limited bucco-palatal width<sup>19,20</sup> (Fig 4). On the other hand, dome-shaped elevations without exposure of lateral and medial walls are a common occurrence in wide sinuses, creating an environment with a relatively low regenerative potential (Fig 5). New bone formation after tSFE was recently demonstrated to have a strong negative correlation with sinus width. In large cavities (> 15 mm), the amount of newly formed bone was reported to be only 3% after 6 months of healing.<sup>20</sup> This trial is in accordance with a previous radiologic study showing that long-term intrasinus bone cov-

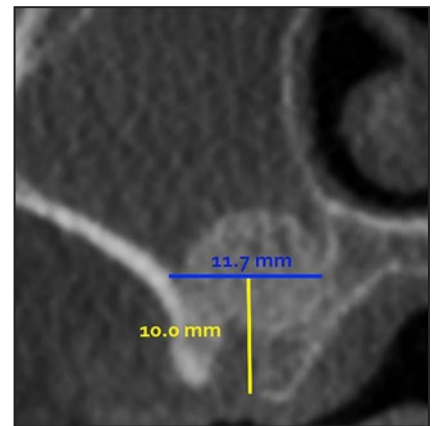


**Fig 2** (above) In the transcresal approach, sinus floor opening may be performed using osteotomes, specially designed burs, or ultrasonic devices, respecting the integrity of the sinus membrane.



**Fig 3** (top right) Sinus membrane elevation may be directly performed by inserting progressive increments of well-hydrated biomaterial.

**Fig 4** (right) In the transcresal approach, adequate membrane elevation (exposing both lateral and medial sinus walls) with the biomaterial in close contact with sinus walls is a predictable outcome only in narrow sinus cavities.



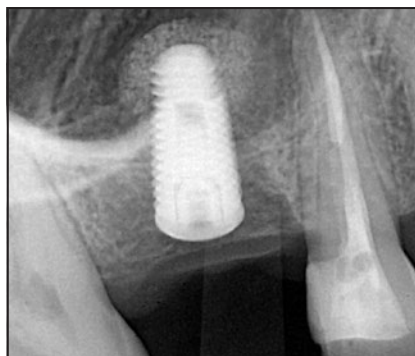
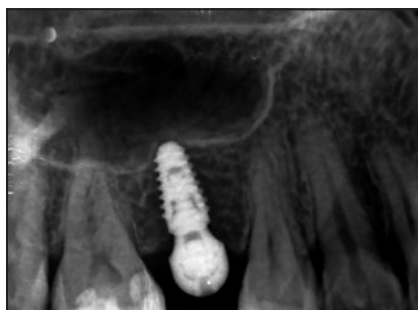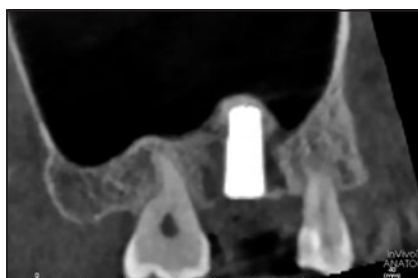
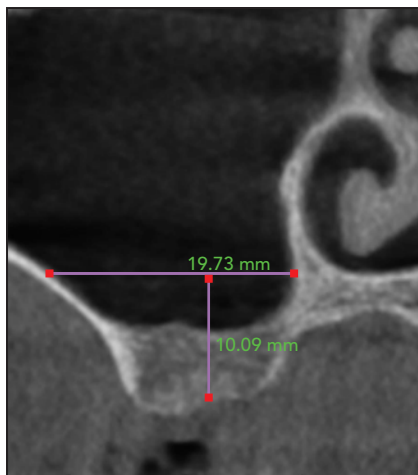
erage of implants after tSFE, which represents an indirect confirmation of satisfactory biologic outcomes and stable clinical results, is more predictable in narrow than in wide sinuses.<sup>21</sup>

Despite this lack of predictability in terms of new bone formation, implants inserted in combination with tSFE achieve a survival rate up to 96.0%.<sup>22</sup> However, in the great majority of the studies included in that systematic review, implants were placed in alveolar crests with native bone height > 5 mm, in which the support of newly formed tissue was not crucial for implant survival.

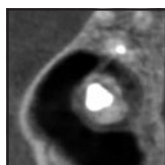
### Short Implants Below the Maxillary Sinus

Himmlová et al described the pattern of distribution of occlusal forces along the bone-implant interface, demonstrating that maximum stress concentration occurs in the crestal portion of the implant (the top 5 to 6 mm).<sup>23</sup> This finding represents the main rationale for using dental implants of reduced length.

The definition of short implants has varied considerably over the years. Currently, the most accepted parameter is to consider short implants as those ≤ 8 mm in length and ultrashort as those < 6 mm in



**Fig 5** Dome-shaped elevations, with inadequate membrane elevation and without contact between the biomaterial and the sinus walls, are a common occurrence in wide sinuses, creating an environment with a relatively low regenerative potential.



**Fig 6** When an implant tip penetrates 1 to 2 mm into the sinus cavity, even in the presence of sinus membrane perforation, complete healing with full coverage of newly formed membrane as well as partial new bone formation can be obtained.

length.<sup>24</sup> Studies conducted in the early 2000s, shortly after the introduction of short implants, demonstrated lower survival rates compared to standard-length implants.<sup>25</sup> Nowadays, however, due to constant technologic improvements in macro- and microdesign of the implants, short implants are associated with predictable long-term clinical outcomes.<sup>26</sup>

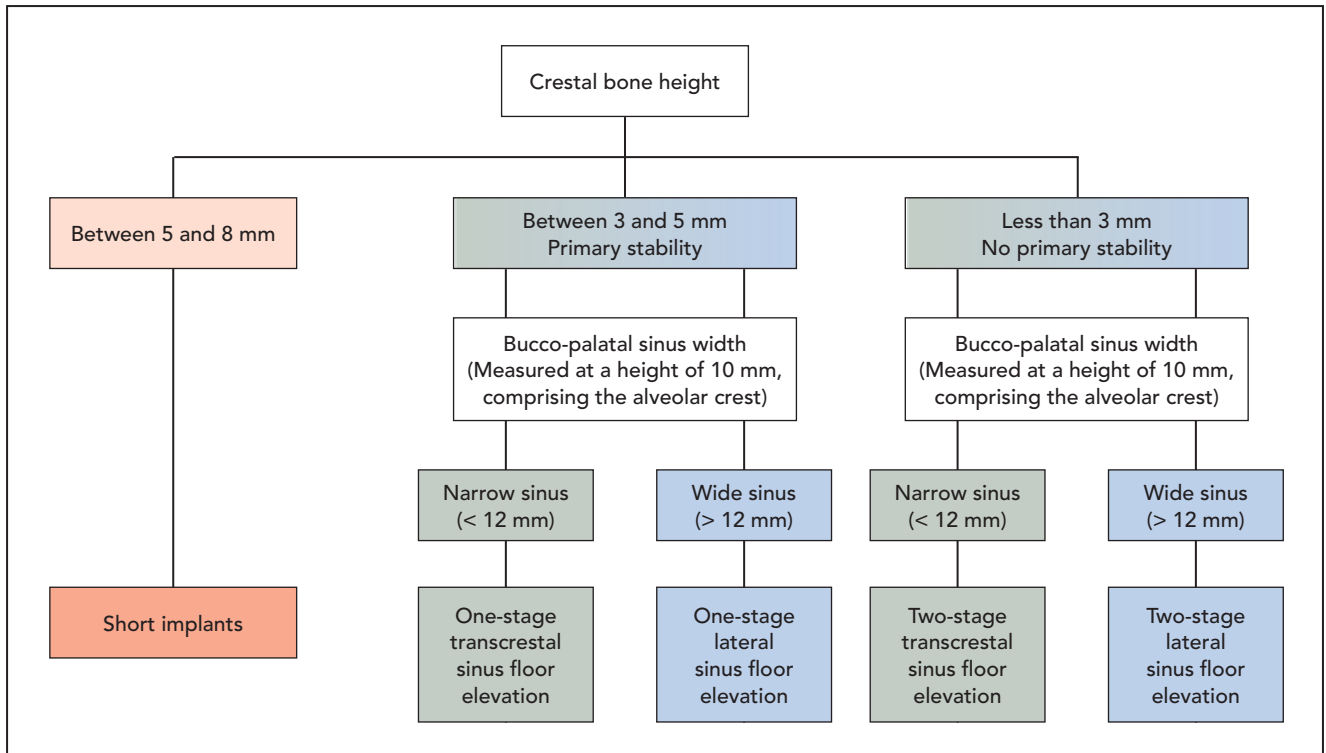
Short and ultrashort implants (normally between 5 and 8 mm) represent a minimally invasive treatment option for the edentulous posterior maxilla. Recent randomized clinical trials support the use of short and ultrashort implants as a fast and predictable treatment alternative,<sup>27,28</sup> both for splinted and single-unit implant-supported restorations. Short implants inserted in

the posterior maxilla, in comparison to longer implants inserted in augmented sinuses, demonstrated a similar medium-term survival rate, with a lower incidence of complications and a tendency towards better peri-implant marginal bone stability. Additionally, placement of a short implant entails significantly lower morbidity and reduced treatment time and cost in comparison with longer implants inserted in regenerated bone.

Implant primary stability may be improved by obtaining bicortical anchorage of the implant with a slight penetration of the sinus floor. From a biologic point of view, one study conducted on animal models showed that, when tips of implants penetrated 1 to 2 mm into the sinus cavity in the presence of sinus membrane perforation, complete healing with full coverage of newly formed membrane and partial new bone formation was obtained<sup>29</sup> (Fig 6). Moreover, a long-term clinical study ranging over a period of up to 20 years indicated that no sinus complications were observed following implant tip penetration into the maxillary sinus.<sup>30</sup> Ng et al, in a very recent retrospective study with up to 5 years of follow-up, demonstrated a 100% survival rate for 6-mm implants inserted with bicortical engagement on the sinus floor; conversely, the same implants placed with monocortical anchorage reached only 52% survival rate at the same time point.<sup>31</sup>

Particular attention should be paid to marginal bone preservation around short implants. This issue, crucial for all implants in preventing





**Fig 7** A decision tree for minimally invasive management of the atrophic posterior maxilla.

peri-implant pathologies, is even more important when dealing with implants of reduced length, in which 1 or 2 mm of bone resorption also represents a significant decrease in total bony support. Implant characteristics (platform-switched internal connection or tissue-level implants)<sup>32</sup> and prosthetic features (screwed prosthesis, abutment longer than 2 mm, adequate occlusion)<sup>33</sup> should be carefully evaluated and selected by the clinician in order to minimize marginal bone resorption.

## Decision Tree

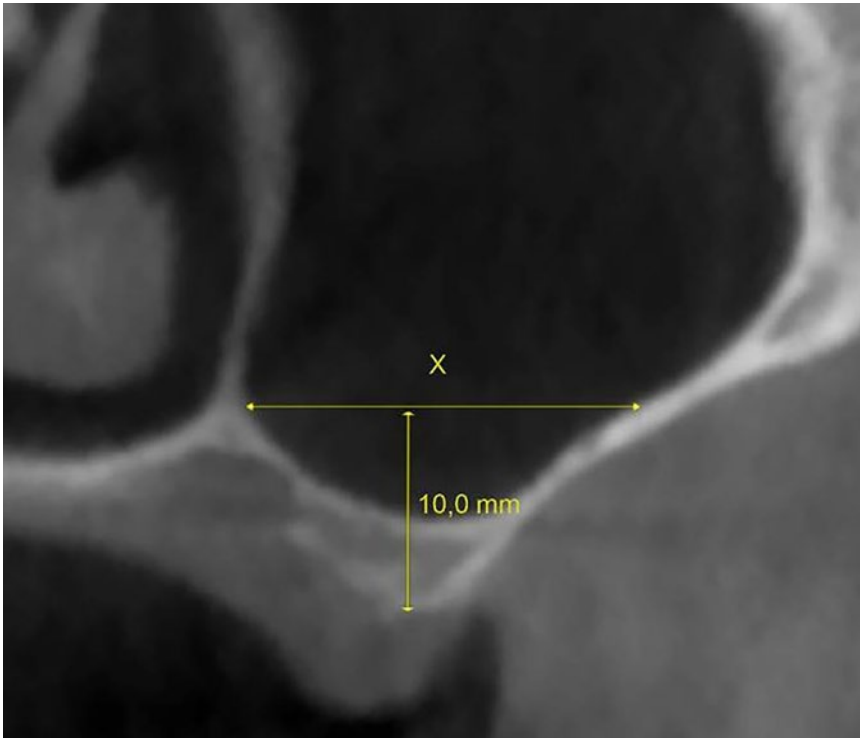
If, after evaluating intermaxillary relationships, the clinician decides that vertical ridge augmentation proce-

dures are not necessary to obtain an acceptable implant-supported rehabilitation in the posterior maxilla, three main clinical scenarios may be outlined (Fig 7).

The first scenario occurs in the presence of a residual ridge height ranging between 5 and 8 mm. In this case, short and ultrashort implants (normally between 5 and 8 mm) may represent the treatment of choice. This approach is minimally invasive, morbidity is very limited, and duration and cost of treatment are the lowest possible when considering implant-supported rehabilitations. An exception could be represented by patients with severe parafunctional habits and poor bone quality, with available bone height < 7 mm; in these selected cases, grafting

procedures could be advantageous in order to place a longer implant.<sup>34</sup>

The second scenario occurs in the presence of a residual ridge height ranging between 3 and 5 mm. In this case, lateral sinus augmentation procedures are necessary to regenerate a suitable amount of bone for standard-length implant placement. However, more recently, implants inserted in combination with transcrestal techniques have obtained high survival rates, even in the presence of a < 5-mm residual bone height,<sup>18–20</sup> though this surgical approach seems to be more appropriate and predictable in narrow rather than in wide sinuses.<sup>21</sup> In fact, recent histologic and histomorphometric analyses confirmed that the tSFE is predictable in terms of new



**Fig 8** The sinus width has to be measured using cone beam computed tomography cross-sections corresponding to the exact position where the implant is to be placed. The distance between the buccal and palatal walls is measured at a height of 10 mm, including the residual crest.

bone formation only in narrow sinus cavities, irrespective of residual crestal height.<sup>19,20</sup> For this reason, evaluation of the sinus bucco-palatal width is fundamental when selecting the best regenerative option for a patient, coupling minimal invasiveness and predictability of clinical outcomes. Sinus width has to be measured using cone beam computed tomography cross-sections corresponding to the exact position where the implant is to be placed. The distance between the buccal and palatal walls is measured at a height of 10 mm, including the residual crest (Fig 8).<sup>13,20,21</sup> A 12-mm width between buccal and palatal walls represents the threshold separat-

ing narrow (< 12 mm) and wide (> 12 mm) sinuses.<sup>19,21</sup> Stacchi et al demonstrated that, when sinus width was divided into three groups (< 12 mm, 12 to 15 mm, and > 15 mm; corresponding to narrow, medium, and wide anatomical patterns), the new bone formations 6 months after tSFE were significantly different (36%, 13%, and 3%, respectively).<sup>20</sup> Therefore, during presurgical planning, bucco-palatal sinus width should be considered one of the critical parameters when selecting between transcresal and lateral approaches in sinus floor elevation.

To summarize: In ridges between 3 to 5 mm in height, lateral sinus elevation seems more

appropriate in the presence of a wide sinus whilst tSFE may be preferred in narrow sinuses—with simultaneous implant placement in both cases—provided that good primary implant stability can be achieved. The one-stage surgical approach, when applicable, is advantageous in terms of time and cost for both the patient and the operator.

In the third scenario (less than 3 mm of residual crestal height), implant primary stability is unpredictable, being related to different variables such as implant design, bone quality, and operator skills. In addition, it seems that implants placed 6 months after lateral sinus elevation present a higher survival rate and greater bone-to-implant contact compared to implants inserted simultaneously with augmentation procedures.<sup>35</sup>

Therefore, in this third clinical scenario, sinus floor elevation with delayed implant placement is the preferred option. The lateral approach could be selected as the therapy of choice both in the presence of wide and narrow sinuses. Nevertheless, in agreement with some studies,<sup>19,20</sup> a staged tSFE approach could also be proposed in the presence of narrow sinuses, even with minimal crestal bone height, in order to minimize invasiveness and morbidity. However, further clinical trials are recommended to corroborate the evidence for this therapeutic option. Both in lateral and transcresal staged approaches, the use of a biomaterial allowing efficient space-maintaining management is mandatory to achieve predictable regenerative results.

## Conclusions

Many advances have been made in implant-supported treatment of the atrophic posterior maxilla. In particular, the use of short implants and tSFE techniques have been widely investigated and developed. Nevertheless, guidelines for selecting the most convenient approach are not up to date with current evidence and, in clinical reality, remain mostly based on the personal experience and skills of the surgeon. This decision tree proposes a minimally invasive approach, based on current evidence, to help the clinician safely and predictably manage the implant-supported rehabilitation of the atrophic posterior maxilla.

## Acknowledgments

The authors declare no conflicts of interest.

## References

- Chiapasco M, Zaniboni M. Methods to treat the edentulous posterior maxilla: Implants with sinus grafting. *J Oral Maxillofac Surg* 2009;67:867–871.
- Nevins M, Camelo M, De Paoli S, et al. A study of the fate of the buccal wall of extraction sockets of teeth with prominent roots. *Int J Periodontics Restorative Dent* 2006;26:19–29.
- Wang HL, Katranji A. ABC sinus augmentation classification. *Int J Periodontics Restorative Dent* 2008;28:383–389.
- Pramstraller M, Farina R, Franceschetti G, Pramstraller C, Trombelli L. Ridge dimensions of the edentulous posterior maxilla: A retrospective analysis of a cohort of 127 patients using computerized tomography data. *Clin Oral Implants Res* 2011;22:54–61.
- Wallace SS, Froum SJ. Effect of maxillary sinus augmentation on the survival of endosseous dental implants. A systematic review. *Ann Periodontol* 2003; 8:328–343.
- Avila-Ortiz G, Wang HL, Galindo-Moreno P, Misch CE, Rudek I, Neiva R. Influence of lateral window dimensions on vital bone formation following maxillary sinus augmentation. *Int J Oral Maxillofac Implants* 2012;27:1230–1238.
- Baldini N, D'Elia C, Bianco A, Goracci C, de Sanctis M, Ferrari M. Lateral approach for sinus floor elevation: Large versus small bone window—A split-mouth randomized clinical trial. *Clin Oral Implants Res* 2017;28:974–981.
- Tükel HC, Tatli U. Risk factors and clinical outcomes of sinus membrane perforation during lateral window sinus lifting: Analysis of 120 patients. *Int J Oral Maxillofac Surg* 2018;47:1189–1194.
- Stacchi C, Andolsek F, Berton F, Perinetti G, Navarra CO, Di Lenarda R. Intraoperative complications during sinus floor elevation with lateral approach: A systematic review. *Int J Oral Maxillofac Implants* 2017;32:e107–e118.
- Stacchi C, Vercellotti T, Toschetti A, Speroni S, Salgarello S, Di Lenarda R. Intraoperative complications during sinus floor elevation using two different ultrasonic approaches: A two-center, randomized, controlled clinical trial. *Clin Implant Dent Relat Res* 2015;17:e117–e125.
- Stacchi C, Lombardi T, Cusimano P, et al. Bone scrapers versus piezoelectric surgery in the lateral antrostomy for sinus floor elevation. *J Craniofac Surg* 2017; 28:1191–1196.
- Flanagan D. Arterial supply of maxillary sinus and potential for bleeding complication during lateral approach sinus elevation. *Implant Dent* 2005;14:336–338.
- Soardi CM, Spinato S, Zaffe D, Wang HL. Atrophic maxillary floor augmentation by mineralized human bone allograft in sinuses of different size: An histologic and histomorphometric analysis. *Clin Oral Implants Res* 2011;22:560–566.
- Summers RB. A new concept in the maxillary implant surgery: The osteotome technique. *Compend* 1994;15:152–160.
- Trombelli L, Franceschetti G, Stacchi C, et al. Minimally invasive transcrestal sinus floor elevation with deproteinized bovine bone or  $\beta$ -tricalcium phosphate: A multicenter, double-blind, randomized, controlled clinical trial. *J Clin Periodontol* 2014;41:311–319.
- Cosci F, Luccioli M. A new sinus lift technique in conjunction with placement of 265 implants: A 6-year retrospective study. *Implant Dent* 2000;9:363–368.
- Troedhan A, Kurrek A, Wainwright M, Jank S. Schneiderian membrane detachment using transcrestal hydrodynamic ultrasonic cavitation sinus lift: A human cadaver head study and histologic analysis. *J Oral Maxillofac Surg* 2014;72: 1503.e1–1503.e10.
- Gonzalez S, Tuan MC, Ahn KM, Nowzari H. Crestal approach for maxillary sinus augmentation in patients with  $\leq 4$  mm of residual alveolar bone. *Clin Implant Dent Relat Res* 2014;16:827–835.
- Lombardi T, Stacchi C, Berton F, Traini T, Torelli L, Di Lenarda R. Influence of maxillary sinus width on new bone formation after transcrestal sinus floor elevation: A proof-of-concept prospective cohort study. *Implant Dent* 2017;26:209–216.
- Stacchi C, Lombardi T, Ottonelli R, Berton F, Perinetti G, Traini T. New bone formation after transcrestal sinus floor elevation was influenced by sinus cavity dimensions: A prospective histologic and histomorphometric study. *Clin Oral Implants Res* 2018;29:465–479.
- Spinato S, Bernardello F, Galindo-Moreno P, Zaffe D. Maxillary sinus augmentation by crestal access: A retrospective study on cavity size and outcome correlation. *Clin Oral Implants Res* 2015;26:1375–1382.
- Emmerich D, Att W, Stappert C. Sinus floor elevation using osteotomes: A systematic review and meta-analysis. *J Periodontol* 2005;76:1237–1251.
- Himmlová L, Dostálová T, Káčovský A, Konvicková S. Influence of implant length and diameter on stress distribution: A finite element analysis. *J Prosthet Dent* 2004;91:20–25.
- Thoma DS, Zeltner M, Hüsler J, Hämmerle CH, Jung RE. EAO Supplement Working Group 4 - EAO CC 2015 Short implants versus sinus lifting with longer implants to restore the posterior maxilla: A systematic review. *Clin Oral Implants Res* 2015;26:154–169.
- Pierrisnard L, Renouard F, Renault P, Barquins M. Influence of implant length and bicortical anchorage on implant stress distribution. *Clin Implant Dent Relat Res* 2003;5:254–262.
- Nisand D, Renouard F. Short implant in limited bone volume. *Periodontol* 2000 2014;66:72–96.

27. Bechara S, Kubilius R, Veronesi G, Pires JT, Shibli JA, Mangano FG. Short (6-mm) dental implants versus sinus floor elevation and placement of longer ( $\geq 10$  mm) dental implants: A randomized controlled trial with a 3-year follow-up. *Clin Oral Implants Res* 2017;28:1097–1107.
28. Pohl V, Thoma DS, Sporniak-Tutak K, et al. Short dental implants (6 mm) versus long dental implants (11-15 mm) in combination with sinus floor elevation procedures: 3-year results from a multi-center, randomized, controlled clinical trial. *J Clin Periodontol* 2017;44:438–445.
29. Zhong W, Chen B, Liang X, Ma G. Experimental study on penetration of dental implants into the maxillary sinus in different depths. *J Appl Oral Sci* 2013;21:560–566.
30. Abi Najm S, Malis D, El Hage M, Rahban S, Carrel JP, Bernard JP. Potential adverse events of endosseous dental implants penetrating the maxillary sinus: Long-term clinical evaluation. *Laryngoscope* 2013;123:2958–2961.
31. Ng P, Hu X, Wan S, Mo H, Deng F. Clinical outcomes of bicortical engagement implants in atrophic posterior maxillae: A retrospective study with 1 to 5 years follow-up. *Int J Periodontics Restorative Dent* 2018;38:e96–e104.
32. Galindo-Moreno P, Fernández-Jiménez A, O'Valle F, et al. Influence of the crown-implant connection on the preservation of peri-implant bone: a retrospective multifactorial analysis. *Int J Oral Maxillofac Implants* 2015;30:384–390.
33. Spinato S, Stacchi C, Lombardi T, Bernardello M, Messina M, Zaffe D. Biological width establishment around dental implants is influenced by abutment height irrespective of vertical mucosal thickness: A cluster randomized controlled trial. *Clin Oral Implants Res* 2019;30:649–659.
34. Chrcanovic BR, Kisch J, Albrektsson T, Wennerberg A. Analysis of risk factors for cluster behavior of dental implant failures. *Clin Implant Dent Relat Res* 2017;19:632–642.
35. Menicucci G, Mussano F, Schierano G, et al. Healing properties of implants inserted concomitantly with anorganic bovine bone. A histomorphometric human study. *Aust Dent J* 2013;58:57–66.