Implant Primary and Secondary Stability after Site Preparation with Electromagnetic Osteotomes or Osseodensification Burs: a Randomized Controlled Trial with Split-Mouth Design

Antonio Rapani[1], Sara Bonaventura[1], Rebecca Martini[1], Federico Berton[1], Riccardo Pasquali[1], Michele Maglione[1], Claudio Stacchi[2]

[1]Department of Medical, Surgical and Health Sciences, University of Trieste, 34129 Trieste, Italy.
[2]Department of Medicine, LUM University, 70010 Casamassima (BA), Italy.

Corresponding Author:
Antonio Rapani
Piazza Ospitale 1, 34129, Trieste
Italy
Phone: 0403992763
E-mail: rapani.antonio@gmail.com

ABSTRACT

Objectives: The purpose of this split-mouth randomized clinical trial is to compare implant primary and secondary stability over 90 days following site preparation with electromagnetic osteotomes or osseodensification burs.
Material and Methods: Nineteen patients received two identical implants in contralateral posterior maxillary sites. Test sites were prepared with electromagnetic osteotomes (EO), and control sites were prepared with osseodensification burs (ODB), reaching the same osteotomy diameter. Resonance frequency analysis (RFA) was recorded at implant placement and after 7, 14, 21, 28, 60 and 90 days. Surgical time, final insertion torque and eventual complications were recorded. Radiographic marginal bone levels were assessed at surgery (T0), prosthesis delivery (T1), and 1 year after loading (T2).
Results: Median final insertion torque did not differ significantly in the two techniques (EO: 58 [IQR 23] Ncm; ODB: 61 [IQR 21.5] Ncm; $P = 0.15$). Baseline implant stability quotient (ISQ) was significantly higher in ODB sites (75.19 [SD 4.95]) than in EO sites (70.66 [SD 6.03]) ($P = 0.004$). Mean ISQ values were significantly higher in the ODB group at all timepoints ($P < 0.05$). Marginal bone levels showed no significant differences between techniques at T1 or T2, and final insertion torque was the only variable significantly associated with initial bone remodeling ($P = 0.016$). All inserted implants were in function at T2.
Conclusions: Within the limitations of this randomized controlled trial conducted in posterior maxillary sites with low bone density, osseodensification burs resulted in significantly higher implant stability, as measured by ISQ values at placement and during early healing, compared with electromagnetic osteotomes, despite similar insertion torque values. Multivariate analysis revealed a significant association between insertion torque and early radiographic changes in marginal bone levels, independent of the preparation technique.

Keywords: bone density; dental implants; maxilla; osseointegration; resonance frequency analysis; treatment outcome.

Accepted for publication: 29 March 2026
To cite this article:
Rapani A, Bonaventura S, Martini R, Berton F, Pasquali R, Maglione M, Stacchi C.
Implant Primary and Secondary Stability after Site Preparation with Electromagnetic Osteotomes or Osseodensification Burs: a Randomized Controlled Trial with Split-Mouth Design
J Oral Maxillofac Res 2026;17(1):e2
URL: http://www.ejomr.org/JOMR/archives/2026/1/e2/v17n1e2.pdf
doi: 10.5037/jomr.2026.17102

INTRODUCTION

Achieving adequate primary stability is a fundamental requirement for predictable osseointegration of dental implants. This initial stability is influenced by several factors, including bone density, implant macro- and micro-geometry, and the underpreparation of the implant bed [1]. In the posterior maxilla, where bone density is often low and reduced cortical thickness is common, achieving sufficient primary stability remains a clinical challenge. Inadequate primary stability can lead to excessive implant micro-movements at the bone-implant interface during early healing, compromising osseointegration and increasing the risk of early implant failure [2-4].

Conventional implant site preparation is traditionally performed through sequential drilling techniques, which remove bone during osteotomy preparation. While this conventional drilling approach is well established in implant site preparation, it inevitably disrupts the trabecular architecture by damaging or fracturing cancellous trabeculae, which can reduce the available micro-anchorage for implant threads, making the achievement of optimal primary stability more challenging. Conversely, excessive compression or friction during implant insertion in excessively undersized osteotomies can induce cortical microfractures and thermal injury, which trigger an inflammatory response and delaying bone healing [5-7].

To overcome these limitations, compactive techniques have been developed to enhance bone quality and implant stability in low-density areas.

Among the available approaches, osseodensification burs (ODB) and electromagnetic osteotomes (EO) are conservative, non-subtractive techniques designed to enhance implant stability in low-density bone. Both methods aim to condense bone along the osteotomy walls, thereby increasing the amount of peri-implant bone available for osseointegration. Osseodensification employs specially designed burs rotating counterclockwise to compact bone through controlled deformation and lateral displacement of bone tissue, potentially increasing peri-implant bone density and improving primary stability. Recent evidence suggests that this approach may enhance implant stability and peri-implant bone density, particularly in low-density bone conditions [8]. EO apply controlled impulses that condense bone through brief, high-intensity impacts, allowing accurate force delivery compared to conventional manual osteotome. Also this approach may improve implant site preparation in low-density bone; however, it remains technique-sensitive and may be associated with localized stress concentration if not properly controlled [9-12].

Previous investigations have demonstrated that osseodensification can improve implant stability and promote faster biological integration compared with conventional drilling. Similarly, electromagnetic osteotomes have shown favourable outcomes in sinus floor elevation, ridge expansion, and implant site preparation, suggesting reduced surgical trauma and predictable osseointegration [13,14]. Although both techniques aim to enhance implant stability through bone compaction, they are based on different biomechanical principles (continuous rotational densification versus intermittent, impact-driven condensation) and their clinical performance has yet to be clearly established.

To the best of our knowledge, no studies have directly compared electromagnetic osteotomes and osseodensification burs used for implant site preparation in low-density posterior maxillary sites. Therefore, the aim of this split-mouth randomized clinical trial was to compare implant primary and secondary stability, as well as early marginal bone level changes, following implant site preparation with electromagnetic osteotomes and osseodensification burs in low-density maxillary bone.

MATERIAL AND METHODS

Study design

This investigation was designed as a split-mouth randomized controlled clinical trial and carried out at the Department of Maxillofacial Surgery and Odontostomatology of the University of Trieste (Trieste, Italy) between February 1, 2024 and October 31, 2025. The trial was conducted and reported in accordance with the CONSORT (Consolidated Standards of Reporting Trials) guidelines for randomized clinical studies.

The study protocol complied with the principles of the Declaration of Helsinki (last revision 2024) and received approval from the Regional Ethical Committee of Friuli Venezia Giulia, Italy (No. CE: 2024-IND-9). In line with international standards for human clinical research, the trial was recorded in a public database of clinical trials - ClinicalTrials.gov (registration no. NCT06679894). Written informed consent was obtained from each participant prior to inclusion, authorizing the collection and use of clinical data and radiographic images for research purposes.

The primary objective of this clinical trial was to compare implant primary and secondary stability achieved after site preparation with EO (test group) or

ODB (control group) in low-density maxillary bone.
The secondary objectives were to determine whether the type of site preparation technique influenced initial bone remodeling during the first year of function, to explore potential correlations between final insertion torque, implant stability quotient (ISQ), and initial bone remodeling, and to compare the operative time required for each protocol. In addition, all intraoperative and postoperative complications were systematically recorded to evaluate the overall safety and clinical performance of both techniques.
All clinical procedures were performed by a single experienced operator (C.S.) to ensure consistency in the surgical technique, while data collection and statistical analyses were carried out by an independent, blinded investigator (A.R.) who was not involved in the treatment phase.

Patient population

Patients requiring implant-supported rehabilitation in two contralateral posterior maxillary edentulous sites, were screened for eligibility. Each candidate underwent a comprehensive medical, dental, and radiographic assessment, including periapical radiographs and cone-beam computed tomography (CBCT) to evaluate bone quality, height, and width.
Eligibility for study participation was determined according to the following inclusion and exclusion criteria.
Inclusion criteria:

- Age ≥ 18 years.
- Indication for implant-supported rehabilitation in two contralateral edentulous sites in the premolar or first-molar region of the maxilla.
- Healed edentulous ridge (≥ 6 months after extraction) without prior grafting or bone augmentation procedures.
- Residual bone height ≥ 10 mm and crestal width ≥ 6 mm, as measured on CBCT.
- Bone quality classified as D3 (porous cortical bone with fine trabeculae) or D4 (very thin cortical bone with low-density trabeculae) according to Misch classification [15].
- Supracrestal tissue height ≥ 3 mm.
- Good oral hygiene and motivation (plaque index ≤ 20%, bleeding on probing ≤ 10%).
- Ability to attend all follow-up visits and provide written informed consent.

Exclusion criteria:

- Acute myocardial infarction within the previous 6 months.
- Uncontrolled bleeding disorders or coagulopathies.
- Uncontrolled diabetes mellitus (HbA1c > 7.5%).
- Radiotherapy to the head or neck region within the previous 48 months.
- Immunocompromised condition or ongoing chemotherapy.
- Current or past intravenous antiresorptive therapy.
- Psychiatric or psychological disorders interfering with compliance.
- Alcohol or drug abuse.
- Heavy smoking (> 10 cigarettes per day).
- Poor oral hygiene or untreated periodontal disease.
- History of benign paroxysmal positional vertigo [16].
- Pregnancy or lactation.
- Refusal to participate or to comply with follow-up visits.

Randomization

Randomization was carried out prior to the clinical phase by an independent investigator who had no role in patient recruitment, surgery, or outcome assessment (R.M.). A computer-generated allocation list was created using an online randomization platform (www.randomization.com), employing permuted blocks of variable size to ensure balanced assignment of the two preparation techniques. For each patient, the random sequence designated one of the two contralateral maxillary sites as the first to be treated with either the test or control group. Allocation codes were placed into sequentially numbered, identical, opaque sealed envelopes to guarantee allocation concealment. Immediately after flap elevation and before osteotomy initiation, the investigator opened the next envelope in sequence and disclosed the assigned technique for the first site; the contralateral site was automatically assigned to the alternative protocol, as per the split-mouth design. Surgeons remained unaware of group allocation until envelope opening, thereafter, neither the operator nor the patient was blinded, while all postoperative stability measurements were performed by a different blinded examiner (S.B.).

Presurgical preparation

One week before surgery, all patients underwent professional oral hygiene recall visit and were instructed to rinse with 0.2% chlorhexidine three times daily, starting three days before surgery.
Patients received amoxicillin 2 g (Zimox® - Pfizer; New York, USA) orally one hour before surgery as antibiotic prophylaxis and clarithromycin 500 mg (Klacid® - Abbott Laboratories; Illinois, USA) was used in those allergic to penicillin.

Immediately before surgery, all patients rinsed with 0.2% chlorhexidine for one minute to reduce intraoral bacterial load.

Surgical protocol

After local anaesthesia using 2% mepivacaine with epinephrine 1 : 100,000 (Carbocaine® - Dentsply Sirona; Charlotte, NC, USA), a minimally invasive full-thickness flap was elevated and the two contralateral sites in the posterior maxilla were randomly assigned to one of the two site preparation techniques before implant placement.
At the test sites, the osteotomy was performed using a sequence of three EO (Magnetic Mallet® - Meta Ergonomica S.r.l.; Milan, Italy) with progressively increasing diameter 2.2 - 2.8 - 3.2 mm, operating at 750 to 1300 N (Figure 1A, B, C and Figure 2).
At the control sites, osteotomy preparation was performed under abundant saline irrigation using a sequence of three ODB (Densah® - Versah, LLC; Jackson, Michigan, USA) with progressively increasing diameters 0.9 - 2.2 - 3.3 mm, with the latter two operated in counterclockwise osseodensification mode at 1200 rpm (Figure 1D and Figure 3).
In both groups, identical endosseous implants were inserted: 4.0 x 8.5 mm; conical design; moderately rough surface, and platform-switched conical connection (Anyridge® - MegaGen; Gyeongbuk, South Korea).
Implants were placed 1 mm subcrestally using a surgical motor (Implantmed Plus® - W&H; Bürmoos, Austria) with a torque-control system that enabled real-time recording of insertion torque values. A 3 mm high transepithelial abutment (AnyRidge® Octa - MegaGen; Gyeongbuk, South Korea) was connected and tightened to 30 Ncm using a calibrated torque wrench, before the periapical radiograph was taken (Figure 4).
Soft tissues were repositioned and sutured with monofilament Prolene™ 4-0 polypropylene sutures (Ethicon; Pomezia, Roma, Italy) using single interrupted stitches.

Postoperative care

Postoperative medications included ibuprofen 400 mg (Brufen® - Abbott Laboratories; Chicago, IL, USA) up to three times daily as needed for pain control and amoxicillin 1 g twice daily for six days (or clarithromycin 500 mg for penicillin-allergic patients). All patients were instructed to rinse with 0.2% chlorhexidine twice daily starting from the second postoperative day and to continue for seven days.
Sutures were removed after 7 days, and clinical healing was evaluated.

Implant-level measurements

Implant stability was assessed through resonance frequency analysis (RFA) at abutment level using a dedicated device Osstell™ Beacon® (Osstell; Gothenburg, Sweden) with the appropriate transducer (SmartPeg #74 - Osstell; Gothenburg, Sweden).

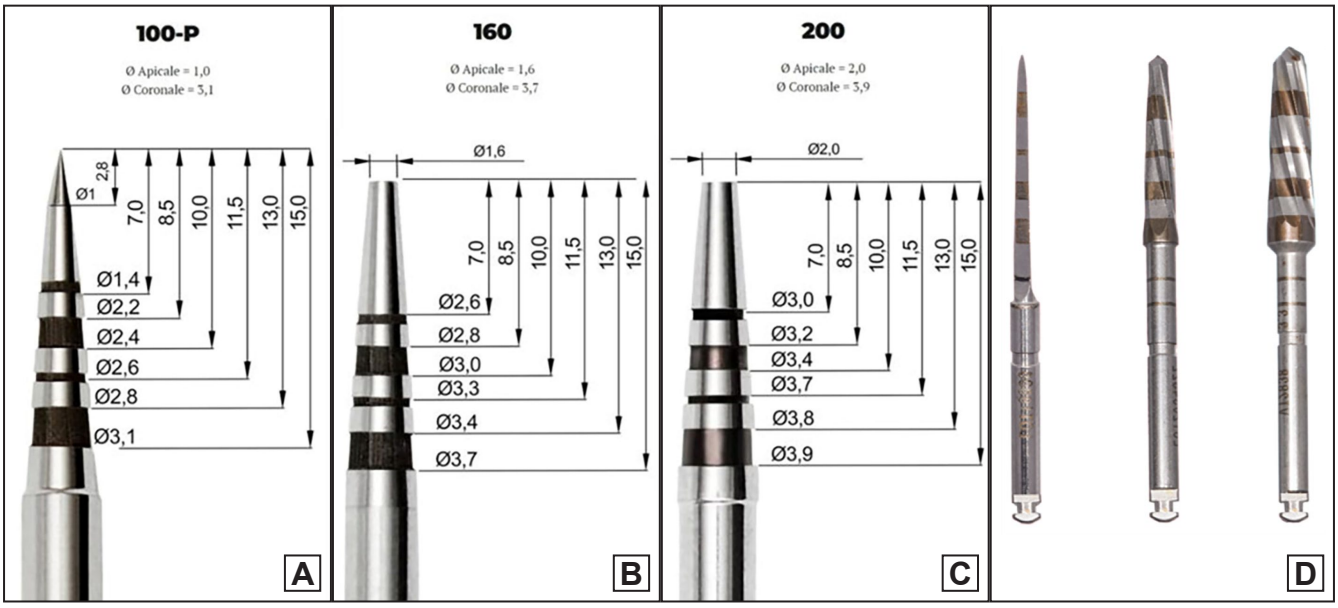

Figure 1. Sequence of instruments used in the test and control groups.
A, B, C = test group, electromagnetic osteotomes (Magnetic Mallet® - Meta Ergonomica S.r.l.): A = Osteotome 100P; B = Osteotome 160; C = Osteotome 200 (Source: Osseotouch LLC; Alabama, USA: www.osseotouch.com/en/products/magnetic-mallet/osteotomes).
D = control group, osseodensification burs (Densah® - Versah, LLC).

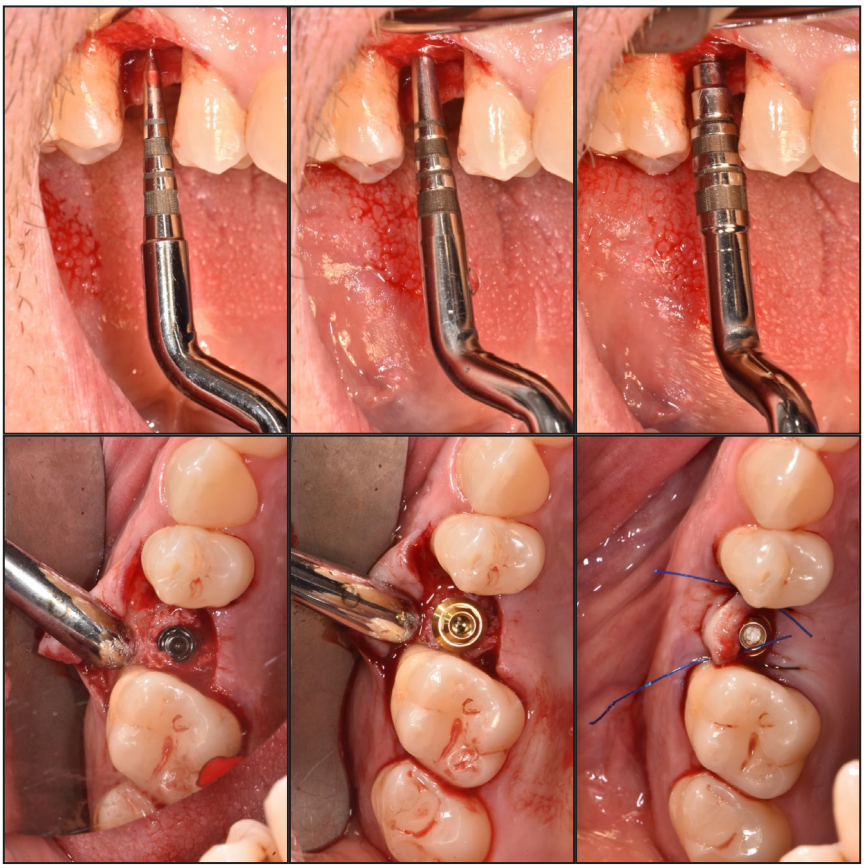

Figure 2. Clinical sequence of implant site preparation and implant positioning in electromagnetic osteotomes (test) group.

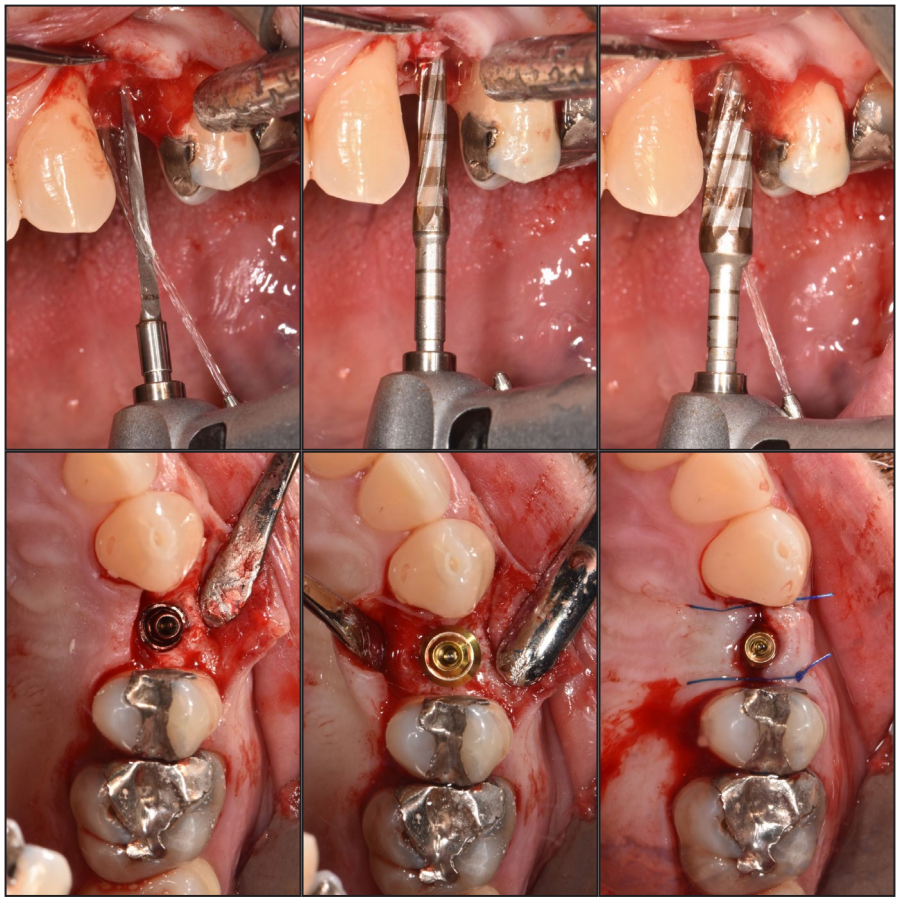

Figure 3. Clinical sequence of implant site preparation and implant positioning in osseodensification burs (control) group.

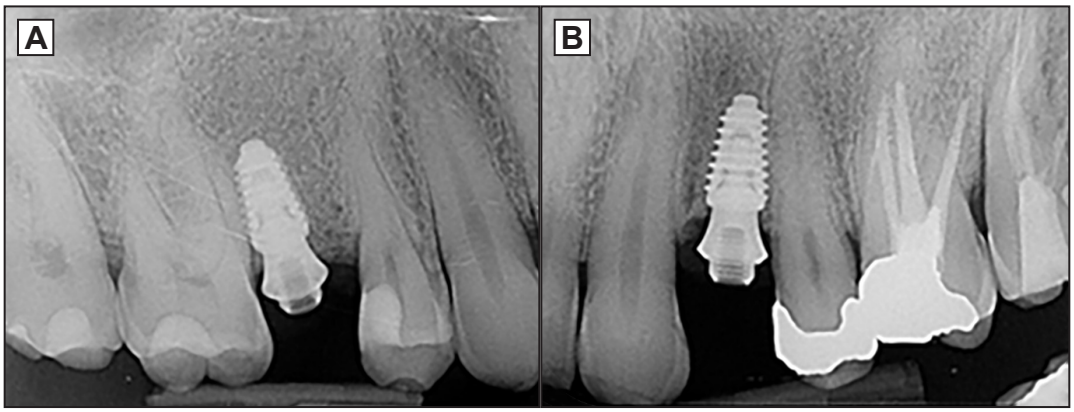

Figure 4. Postoperative radiographs of implants in sites: A = electromagnetic osteotomes; B = osseodensification burs

Measurements were performed in two orthogonal directions (bucco-palatal and mesio-distal) and each measurement was repeated three times per direction. The mean of all readings was used as the representative ISQ value for that time point.

Before averaging, repeated measurements were checked for internal consistency; when differences between readings exceeded 5%, the measurement was repeated to ensure reliability. Measurements were performed at implant insertion and 7, 14, 21, 28, 60 and 90 days after surgery to monitor changes in implant stability over time. The insertion torque recorded during implant placement was used as a complementary indicator of primary stability and for correlation analyses with ISQ and IBR measured at T0 (immediately after surgery), T1 (prosthesis delivery), and T2 (one year after loading).

Initial bone remodelling was assessed radiographically using standardized periapical radiographs, using the implant platform used as a reference point. Measurements were performed using a specific software ImageJ version 1.51 (Fiji distribution; National Institute of Health, Bethesda, Meryland, USA), with calibration based on the actual implant length and diameter.

Sample size calculation

To estimate the required sample size, insertion torque data from previous studies [16,17] were used, as this parameter is reported in literature more consistently for both techniques than ISQ. Reported mean torque values ranged from 50 to 70 Ncm for EO and from 35 to 59 Ncm for ODB.

Assuming a statistical power of 80%, an alpha error of 0.05, and a beta error of 0.2, the minimum sample size corresponded to six paired comparisons between the two techniques.

To increase statistical reliability and compensate potential dropouts, nineteen patients (38 implant sites) were ultimately enrolled.

Statistical analysis

All data were analysed using SPSS® Statistics version 29.0 (IBM; Armonk, New York, USA). Continuous variables were summarized as mean and standard deviation (M [SD]) for normally distributed data and as median and interquartile range (IQR) for non-normally distributed data. Data normality was assessed using the Shapiro-Wilk test. Given the split-mouth design, paired statistical tests were applied for inter-group comparisons, with each patient acting as their own control. The paired Student's t-test was used for parametric variables and the Wilcoxon signed-rank test for non-parametric ones. Comparisons between EO and ODB were performed both on absolute ISQ values and on the percentage change in stability at each time point relative to baseline. Longitudinal changes in implant stability within each group were assessed using repeated-measures ANOVA, with Huynh-Feldt correction applied when the assumption of sphericity (evaluated with Mauchly's test) was violated. For non-parametric data, the Friedman test was used. When overall significance was observed, Bonferroni-adjusted post-hoc tests were applied to control for multiple testing. Surgical time and insertion torque between the two preparation techniques were compared using the paired Student's t-test for normally distributed data or the Wilcoxon signed-rank test for non-normally distributed data. To identify independent predictors of IBR, multivariate linear regression models were constructed at T1 and T2. The level of statistical significance was set at $P < 0.05$.

RESULTS

Twenty-six patients were screening for potential inclusion in the present study and 7 of them were excluded due to the following reasons: 2 declined to participate, and 5 were excluded for general or local

contraindications (Figure 5).

Nineteen patients (12 males and 7 females; mean age 52.5 [SD 14.1] years) were enrolled and treated. Four were smokers and fifteen were non-smokers; six presented a history of periodontal disease and thirteen were periodontally healthy. There was no statistically significant difference in patient gender (P > 0.05) and age (P > 0.05).

During implant site preparation, a buccal cortical plate fracture occurred at one test site (EO). The implant was placed and submerged, and the defect was treated with guided bone regeneration using a xenogeneic graft and a resorbable membrane. Therefore, this site was excluded from the analysis of implant stability changes over time and the final sample consisted of 19 patients (12 males and 7 females) and 37 implants.

No further intraoperative or postoperative complications were recorded, and all implants were functional and clinically stable at the one-year follow-up (Figure 5).

The Shapiro-Wilk test showed that insertion torque and surgical time were non-normally distributed (EO: P = 0.037 and P = 0.034; ODB: P = 0.017 and P = 0.034, respectively), while ISQ and IBR values at all time points were normally distributed (P > 0.05).

The median insertion torque was 58 (IQR 23) Ncm in EO group and 61 (IQR 21.5) Ncm in ODB group. Surgical time showed median values of 366.5 (IQR 187.7) seconds for the EO technique and 252.5 (IQR 106) seconds for the ODB technique. No significant differences in insertion torque or surgical time were observed between the test and control groups (P = 0.15 and P = 0.916, respectively) (Table 1).

Table 1. Insertion torque and surgical time for electromagnetic osteotomes (EO) and osseodensification burs (OD)

Variable	EO	ODB	P-value[a]
	Median (IQR)	Median (IQR)	
Insertion torque (Ncm)	58 (23)	61 (21.5)	0.15
Surgical time (seconds)	366.5 (187.7)	252.5 (106)	0.916

[a]Wilcoxon signed-rank test. *Statistically significant at P < 0.05.
IQR = interquartile range.

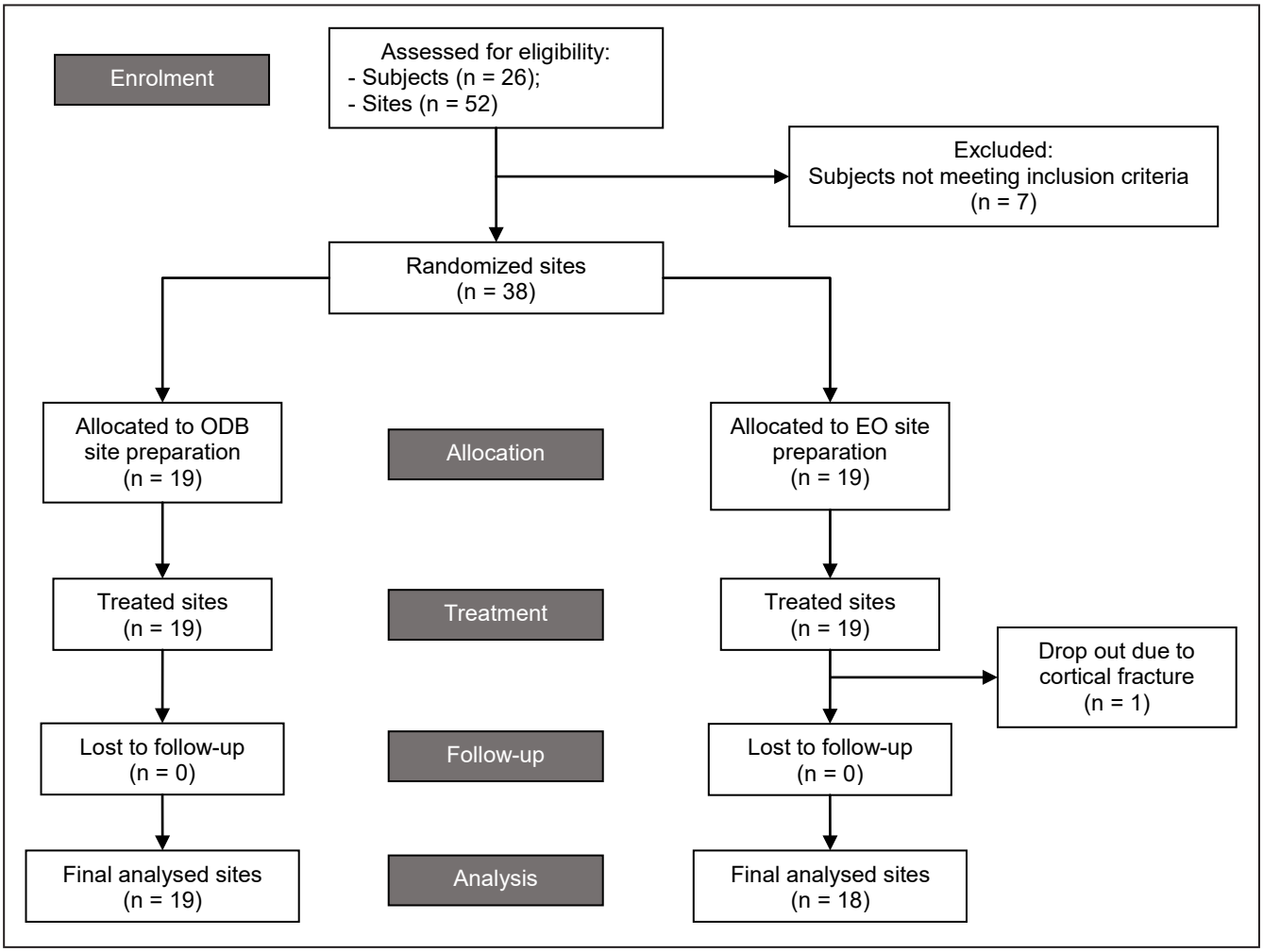

Figure 5. Flow chart summarizing patient enrolment, site allocation, and analytical workflow..

Table 2. Implant stability quotient values at each time point for electromagnetic osteotomes (EO) and osseodensification burs (ODB)

Time point	EO	ODB	95% CI	P-value[a]
	Mean (SD)	Mean (SD)		
Baseline	70.7 (6)	75.2 (4.9)	-6.96; -1.53	0.004*
7 days	68.2 (7.7)	73.8 (5)	-8.58; -1-84	0.004*
14 days	65 (8.5)	71.8 (5.8)	-10.49; -2.11	0.005*
21 days	61.6 (10.9)	69.9 (5.88)	-13.46; -1.97	0.011*
28 days	62.0 (10.96)	71.1 (5.34)	-13.86;-3.01	0.004*
60 days	65.3 (8.16)	73.5 (4.63)	-11.47; -3.75	0.001*
90 days	68 (7.77)	75.5 (4.29)	-10.64; -3.3	0.001*
P-value[a]	0.000*	0.000*	-	-

[a]Paired Student's t-test. *Statistically significant at P < 0.05.
CI = confidence interval; SD = standard deviation.

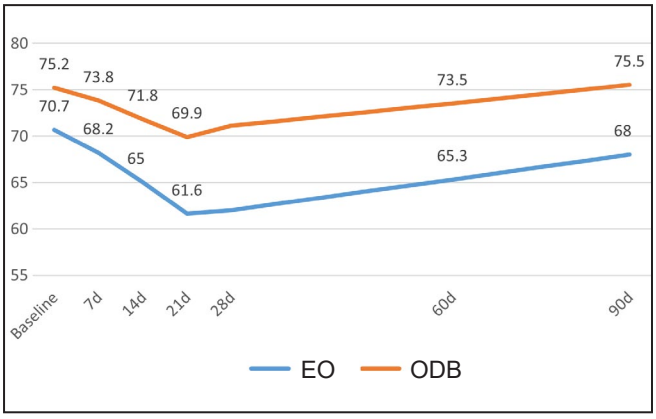

Figure 6. Changes in mean implant stability quotient values of both groups during the first 90 days after implant insertion.
EO = electromagnetic osteotomes; ODB = osseodensification burs.

Conversely, mean baseline ISQ value at T0 was significantly higher in ODB group (75.19 [SD 4.95]) than in EO group (70.66 [SD 6.03]) (P = 0.004) (Table 2).

A reduction in stability was observed during the early healing period for both techniques.

The lowest ISQ values occurred at 21 days after implant placement in both groups, with mean values of 61.56 (SD 10.89) for EO (-13.06% from baseline) and 69.94 (SD 5.88) for ODB (-6.93% from baseline) (P = 0.011) (Table 2).

Complete mean ISQ values and percentual stability variations at each follow-up are presented in Table 2 and 3 and Figure 6 and 7.

Mean interproximal IBR from T0 to T1 was 0.69 (SD 0.42) mm for the EO group and 0.66 (SD 0.62) mm for the ODB group. Between T0 and T2, values were 0.85 (SD 0.49) mm and 0.75 (SD 0.72) mm, respectively. No significant intergroup differences were detected at either interval (Table 4).

Multivariate linear regression identified final insertion torque as the only independent variable significantly associated with IBR at T1 (P = 0.016), while ISQ at T0 and surgical approach (EO vs. ODB) resulted not correlated. At T2, no significant correlations were observed between IBR and any of the investigated variables (P > 0.05) (Table 5).

No implant loss or other adverse events were recorded during the study period.

Table 3. Percentual implant stability loss at each time point for electromagnetic osteotomes (EO) and osseodensification burs (ODB)

Time point	EO (%)	ODB (%)	95% CI	P-value[b]
7 days	-3.7	-1.9	-6.57; -0.21	0.049*
14 days	-8.2	-4.6	-11; -0.8	0.083
21 days	-13.1	-6.9	-12.29; -0.46	0.036*
28 days	-12.5	-5.4	-8.65; -1.32	0.01*
60 days	-7.7	-2.2	-7.23; -0.72	0.019*
90 days	-3.9	0.5	-3.47; -0.28	0.091
P-value[a]	0.000*	0.000*	-	-

[a]Repeated-measures ANOVA for within-group comparisons over time. [b]Paired Student's t-test for between-group comparisons. *Statistically significant at P < 0.05.
CI = confidence interval.

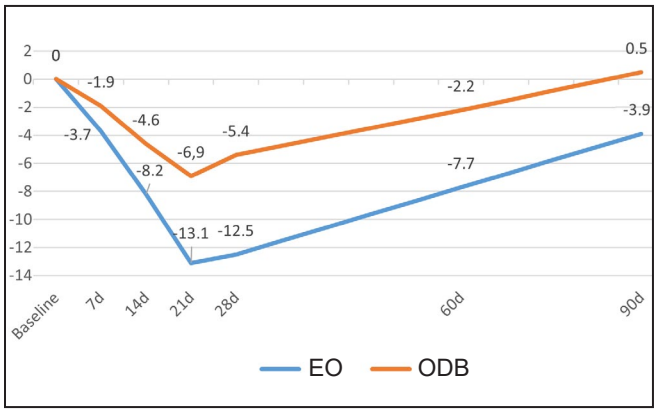

Figure 7. Implant stability quotient percentual decrease in both groups during the first 90 days after implant insertion.
EO = electromagnetic osteotomes; ODB = osseodensification burs.

Table 4. Initial bone remodeling for electromagnetic osteotomes (EO) and osseodensification burs (ODB) between time intervals

Interval	EO (mm)	ODB (mm)	P-value[a]
	Mean (SD)	Mean (SD)	
T0 - T1	0.69 (0.42)	0.66 (0.62)	> 0.05
T0 - T2	0.85 (0.49)	0.75 (0.72)	> 0.05

[a]Paired Student's t-test. *Statistically significant at P < 0.05
T0 = implant placement; T1 = prosthesis delivery; T2 = one year after loading; SD = standard deviation.

Table 5. Multivariate linear regression analysis for predictors of initial bone remodeling

Time point	Variable	β	SE	P-value[a]
T1	Insertion torque	0.479	0.005	0.016*
	ISQ	0.309	0.017	0.114
Technique (EO/ODB)		- 0.281	0.189	0.147
T2	Insertion torque	0.4	0.007	0.059
	ISQ	0.283	0.026	0.167

[a]Multivariate linear regression analysis. *Statistically significant at $P < 0.05$.
T1 = prosthesis delivery; T2 = one year after loading; ISQ = implant stability quotient; EO = electromagnetic osteotomes; ODB = osseodensification burs; β = regression coefficient; SE = standard error of the coefficient.

DISCUSSION

The present split-mouth randomized controlled trial compared implant stability after implant site preparation with EO or ODB. A tapered implant design was used, generally associated with favourable primary stability in low-density bone, allowing a standardized comparison between the two techniques. Measurements at T0 (primary stability) showed significantly higher ISQ in the ODB group, while final insertion torque values did not differ between the two techniques. This lack of direct correspondence between insertion torque and ISQ has been repeatedly described in the literature and reflects the fact that these parameters capture different mechanical dimensions of primary stability [17]. The results of the present study indicate that both techniques produced an implant bed offering similar rotational resistance during implant insertion, whereas the lateral stability of the implant-bone interface was significantly increased when the osteotomy was prepared with ODB. The higher baseline ISQ in the ODB group probably reflects the distinct pattern of lateral bone densification produced by the osseodensification process, which may enhance resistance to implant lateral micromovements more effectively than the intermittent impacts generated by EO. Even if both approaches are classified as compactive techniques, their mechanics differ substantially. EO deliver high-frequency impulses that produce localized radial condensation allowing apical advancement of the instrument [8], whereas ODB create continuous circumferential compaction throughout the osteotomy, resulting in a more uniformly densified peri-implant trabecular structure [9,10].

In the early postoperative period, both groups showed the expected slight decrease in stability, consistent with the well-described "stability dip" linked to transient increased osteoclastic activity related to bone remodeling after surgical trauma [18,19]. ISQ reached its minimum at 21 days for both techniques, with subsequent progressive increase reflecting early new bone formation and the transition from mechanical to biological stability. However, ODB maintained significantly higher ISQ values than EO at 28, 60, and 90 days, suggesting that the enhanced lateral stiffness imparted by the densification process persisted during early remodeling phase, in agreement with previous reports demonstrating increased bone-to-implant contact after non-subtractive densification [9,10,14]. The present findings also align with experimental evidence from Büchter et al. [20], demonstrating that osteotome-based compaction may induce trabecular microfractures in the peri-implant bone, temporarily reducing biomechanical stability before normal bone remodeling restores trabecular structure. Although EO differs from manual osteotomes by delivering controlled impulses, these data suggest that compactive techniques relying on impact forces may transiently compromise trabecular integrity, potentially explaining the lower early lateral stiffness observed in the EO group compared with ODB. Furthermore, only a limited number of human studies have evaluated implant site preparation with EO, and most originate from the same research group, underscoring the need for broader independent clinical validation [21-25].

Surgical time did not differ significantly between groups, confirming similar clinical efficiency. One intraoperative complication occurred in the EO group (buccal plate fracture). Although such events are commonly linked to manual osteotome-based expansion, it is generally assumed, but not yet clearly demonstrated, that the controlled impulses of magnetodynamic devices may reduce this risk [23]. No further complications or implant failures were recorded in the observation period.

Marginal bone level changes did not differ between test and control groups at T1 or T2. Multivariate regression analysis identified final insertion torque, rather than the site preparation method or baseline ISQ, as the only variable significantly associated with initial marginal bone remodeling. This finding supports the concept that excessive cortical strain, regardless of how it is generated, may trigger a more pronounced early resorptive response. This observation is consistent with previous reports linking high insertion torque to cortical microfractures and increased initial bone remodeling [26-29].

The present study has some limitations. The investigation was limited to healed sites in the posterior maxilla with low-density bone (D3 to D4); therefore, the findings cannot be directly extrapolated to other clinical scenarios. In particular, the thicker cortical plates and higher density typical of mandibular bone, as well as D1 to D2 bone types, may respond differently to electromagnetic osteotomes and osseodensification burs. It should be noted, however, that both techniques are primarily intended for low-quality bone, which represents their main clinical indication.

Another limitation relates to the scale properties of ISQ. Although commonly used as a continuous variable in implant research, ISQ is not a strictly linear scale, and equal numerical differences may not fully reflect equivalent changes in implant stability across its range.

Histological evaluation was not performed, for obvious ethical reasons, precluding direct assessment of trabecular reorganization and bone-to-implant contact in the two groups. In addition, only final insertion torque was considered in the analysis; other potentially informative descriptors of the insertion process, such as torque-depth integrals, mean or peak torque, torque curve intercept and slope, quadratic coefficient (β_2), or standard deviation of the residual error (σ_e), were not recorded, despite growing evidence that these parameters may better represent the cumulative mechanical load applied to cortical bone [9,30].

Future investigations with longer follow-up periods and involving different clinical scenarios integrating micro-CT, histomorphometry, and full acquisition of torque curve parameters will help clarify how the distinct compaction vectors produced by these two techniques may influence early osseointegration and peri-implant marginal bone stability.

CONCLUSIONS

Within the limitations of this split-mouth clinical trial, implant site preparation performed in posterior maxillary sites with low-density bone with osseodensification burs resulted in significantly higher primary and secondary stability, when compared with electromagnetic osteotomes, despite similar insertion torque values at baseline. The superior performance of osseodensification could be related to its uniform circumferential lateral bone compaction, which increases peri-implant density and stiffness along the entire osteotomy.

Implant site preparation with electromagnetic osteotomes provided adequate stability for implant placement and predictable healing but showed a lower stability gain during early healing, likely due to its predominantly axial compaction pattern.

No differences were found in surgical time, initial marginal bone remodeling, or 1-year implant survival. Initial bone remodeling showed significant direct correlation with insertion torque, but not with the implant site preparation method or with implant stability quotient at T0.

Further studies are needed to investigate the biomechanical implications of different compaction vectors and to define clinical indications for each technique in low-density bone.

ACKNOWLEDGMENTS AND DISCLOSURE STATEMENTS

The authors report no conflicts of interest related to this study. The study was self-funded.

REFERENCES

1. Huang YC, Huang YC, Ding SJ. Primary stability of implant placement and loading related to dental implant materials and designs: A literature review. J Dent Sci. 2023 Oct;18(4):1467–76. doi:10.1016/j.jds.2023.06.010 PubMed PMID: 37799926.
2. Brunski JB. Biomechanical factors affecting the bone-dental implant interface. Clin Mater. 1992;10(3):153–201. doi:10.1016/0267-6605(92)90049-y PubMed PMID: 10149982.
3. Javed F, Ahmed HB, Crespi R, Romanos GE. Role of primary stability for successful osseointegration of dental implants: Factors of influence and evaluation. Interv Med Appl Sci. 2013 Dec;5(4):162–7. doi:10.1556/IMAS.5.2013.4.3 PubMed PMID: 24381734.
4. Monje A, Ravidà A, Wang HL, Helms JA, Brunski JB. Relationship between primary/mechanical and secondary/biological implant stability. Int J Oral Maxillofac Implants. 2019 Suppl;34:s7–23. doi:10.11607/jomi.19suppl.g1 PubMed PMID: 31116830.
5. Eriksson AR, Albrektsson T. Temperature threshold levels for heat-induced bone tissue injury: a vital-microscopic study in the rabbit. J Prosthet Dent. 1983 Jul;50(1):101–7. doi:10.1016/0022-3913(83)90174-9 PubMed PMID: 6576145.

6. Matthews LS, Hirsch C. Temperatures measured in human cortical bone when drilling. J Bone Joint Surg Am. 1972 Mar;54(2):297–308. PubMed PMID: 4651263.
7. Ercoli C, Funkenbusch PD, Lee HJ, Moss ME, Graser GN. The influence of drill wear on cutting efficiency and heat production during osteotomy preparation for dental implants: a study of drill durability. Int J Oral Maxillofac Implants. 2004;19(3):335–49. PubMed PMID: 15214217.
8. Antonelli A, Barone S, Attanasio F, Salviati M, Cerra MG, Calabria E, Bennardo F, Giudice A. Effect of implant macro-design and magnetodynamic surgical preparation on primary implant stability: An in vitro investigation. Dent J (Basel). 2023 Sep 24;11(10):227. doi:10.3390/dj11100227 PubMed PMID: 37886912.
9. Huwais S, Meyer EG. A novel osseous densification approach in implant osteotomy preparation to increase biomechanical primary stability, bone mineral density, and bone-to-implant contact. Int J Oral Maxillofac Implants. 2017;32(1):27–36. doi:10.11607/jomi.4817 PubMed PMID: 27741329.
10. Trisi P, Berardini M, Falco A, Podaliri Vulpiani M. New osseodensification implant site preparation method to increase bone density in low-density bone: In vivo evaluation in sheep. Implant Dent. 2016 Feb;25(1):24–31. doi:10.1097/ID.0000000000000358 PubMed PMID: 26584202.
11. Crespi R, Capparè P, Gherlone EF. Electrical mallet in implants placed in fresh extraction sockets with simultaneous osteotome sinus floor elevation. Int J Oral Maxillofac Implants. 2013;28(3):869–74. doi:10.11607/jomi.2679 PubMed PMID: 23748321.
12. Bennardo F, Barone S, Vocaturo C, Nucci L, Antonelli A, Giudice A. Usefulness of magnetic mallet in oral surgery and implantology: A systematic review. J Pers Med. 2022 Jan 14;12(1):108. doi:10.3390/jpm12010108 PubMed PMID: 35055423.
13. Gaspar J, Proença L, Botelho J, Machado V, Chambrone L, Neiva R, Mendes JJ. Implant stability of osseodensification drilling versus conventional surgical technique: A systematic review. Int J Oral Maxillofac Implants. 2021;36(6):1104–10. doi:10.11607/jomi.9132 PubMed PMID: 34919606.
14. Stacchi C, Troiano G, Montaruli G, Mozzati M, Lamazza L, Antonelli A, Giudice A, Lombardi T. Changes in implant stability using different site preparation techniques: Osseodensification drills versus piezoelectric surgery. A multi-center prospective randomized controlled clinical trial. Clin Implant Dent Relat Res. 2023 Feb;25(1):133–40. doi:10.1111/cid.13140 PubMed PMID: 36190150.
15. Misch C. Bone density: a key determinant for clinical success. In: Contemporary Implant Dentistry. 2nd ed. Mish CE; 1999. p. 109–18.
16. Valentini P, Stacchi C. Prevention and management of intra-operative complications in maxillary sinus augmentation: A review. Clin Implant Dent Relat Res. 2025 Feb;27(1):e13397. doi:10.1111/cid.13397 PubMed PMID: 39379340.
17. Lages FS, Douglas-de Oliveira DW, Costa FO. Relationship between implant stability measurements obtained by insertion torque and resonance frequency analysis: A systematic review. Clin Implant Dent Relat Res. 2018 Feb;20(1):26–33. doi:10.1111/cid.12565 PubMed PMID: 29194944.
18. Barewal RM, Oates TW, Meredith N, Cochran DL. Resonance frequency measurement of implant stability in vivo on implants with a sandblasted and acid-etched surface. Int J Oral Maxillofac Implants. 2003;18(5):641–51. PubMed PMID: 14579951.
19. Raghavendra S, Wood MC, Taylor TD. Early wound healing around endosseous implants: a review of the literature. Int J Oral Maxillofac Implants. 2005;20(3):425–31. PubMed PMID: 15973954.
20. Büchter A, Kleinheinz J, Wiesmann HP, Kersken J, Nienkemper M, Weyhrother H von, Joos U, Meyer U. Biological and biomechanical evaluation of bone remodelling and implant stability after using an osteotome technique. Clin Oral Implants Res. 2005 Feb;16(1):1–8. doi:10.1111/j.1600-0501.2004.01081.x PubMed PMID: 15642025.
21. Crespi R, Capparè P, Gherlone E. Electrical mallet provides essential advantages in maxillary bone condensing. A prospective clinical study. Clin Implant Dent Relat Res. 2013 Dec;15(6):874–82. doi:10.1111/j.1708-8208.2011.00432.x PubMed PMID: 22235762.
22. Crespi R, Capparè P, Gherlone E. A comparison of manual and electrical mallet in maxillary bone condensing for immediately loaded implants: A randomized study. Clin Implant Dent Relat Res. 2014 Jun;16(3):374–82. doi:10.1111/j.1708-8208.2012.00485.x PubMed PMID: 22897742.
23. Crespi R, Capparè P, Gherlone EF. Electrical mallet provides essential advantages in split-crest and immediate implant placement. Oral Maxillofac Surg. 2014 Mar;18(1):59–64. doi:10.1007/s10006-013-0389-2 PubMed PMID: 23329162.
24. Crespi R, Bruschi GB, Gastaldi G, Capparé P, Gherlone EF. Immediate loaded implants in split-crest procedure. Clin Implant Dent Relat Res. 2015 Oct;17 Suppl 2:e692-698. doi:10.1111/cid.12316 PubMed PMID: 25781900.
25. Baldi D, Colombo J, Cassinotto E, Bagnasco F, DE Giorgis L, Baldi F, Morawiec T, Pesce P, Menini M. Evaluation of the crestal bone expansion obtained with the Magnetic Mallet® during the preparation of the implant site: A case series. Minerva Dent Oral Sci. 2025 Oct;74(5):318–27. doi:10.23736/S2724-6329.25.05106-X PubMed PMID: 40924036.
26. Coyac BR, Leahy B, Salvi G, Hoffmann W, Brunski JB, Helms JA. A preclinical model links osseo-densification due to misfit and osseo-destruction due to stress/strain. Clin Oral Implants Res. 2019 Dec;30(12):1238–49. doi:10.1111/clr.13537 PubMed PMID: 31520494.

27. Duyck J, Roesems R, Cardoso MV, Ogawa T, De Villa Camargos G, Vandamme K. Effect of insertion torque on titanium implant osseointegration: An animal experimental study. Clin Oral Implants Res. 2015 Feb;26(2):191–6. doi:10.1111/clr.12316 PubMed PMID: 24325598.
28. Ottoni JMP, Oliveira ZFL, Mansini R, Cabral AM. Correlation between placement torque and survival of single-tooth implants. Int J Oral Maxillofac Implants. 2005;20(5):769–76. PubMed PMID: 16274152.
29. Stacchi C, Testori T, Rapani A, Arai Y, Avila-Ortiz G, Blanco-Carrión J, Borges T, Bressan E, Canullo L, Galindo-Moreno P, Garaicoa-Pazmiño C, Lin GH, Linkevičius T, Mattheos N, Mikulás K, Monje A, Muñoz M, Padial-Molina M, Ravidà A, Siqueira R, Spinato S, Suárez-López Del Amo F, Tomasi C, Troiano G, Wang HL, Lombardi T. Prevention of initial bone remodelling around dental implants: An international clinical consensus utilising the Delphi method. Int J Oral Implantol (Berl). 2026 Mar 13;19(1):61–74. PubMed PMID: 41823005.
30. Di Stefano DA, Arosio P, Gastaldi G, Gherlone E. The insertion torque-depth curve integral as a measure of implant primary stability: An in vitro study on polyurethane foam blocks. J Prosthet Dent. 2018 Nov;120(5):706–14. doi:10.1016/j.prosdent.2017.04.012 PubMed PMID: 28689908.

To cite this article:
Rapani A, Bonaventura S, Martini R, Berton F, Pasquali R, Maglione M, Stacchi C.
Implant Primary and Secondary Stability after Site Preparation with Electromagnetic Osteotomes or Osseodensification Burs: a Randomized Controlled Trial with Split-Mouth Design
J Oral Maxillofac Res 2026;17(1):e2
URL: http://www.ejomr.org/JOMR/archives/2026/1/e2/v17n1e2.pdf
doi: 10.5037/jomr.2026.17102

Copyright © Rapani A, Bonaventura S, Martini R, Berton F, Pasquali R, Maglione M, Stacchi C. Published in the JOURNAL OF ORAL & MAXILLOFACIAL RESEARCH (http://www.ejomr.org), 31 March 2026.
This is an open-access article, first published in the JOURNAL OF ORAL & MAXILLOFACIAL RESEARCH, distributed under the terms of the Creative Commons Attribution-Noncommercial-No Derivative Works 3.0 Unported License, which permits unrestricted non-commercial use, distribution, and reproduction in any medium, provided the original work and is properly cited. The copyright, license information and link to the original publication on (http://www.ejomr.org) must be included.