Check for updates

Received: 8 December 2022 | Revised: 4 January 2023 | Accepted: 16 January 2023

DOI: 10.1111/cid.13186

ORIGINAL ARTICLE

WILEY

Marginal bone changes around platform-switched conical connection implants placed 1 or 2 mm subcrestally: A multicenter crossover randomized controlled trial

Claudio Stacchi DDS, MSc[1] | Luca Lamazza DDS, PhD[2] | Antonio Rapani DDS, MSc[1] | Giuseppe Troiano DDS, PhD[3] | Marcello Messina DDS[4] | Alessandro Antonelli DDS[5] | Amerigo Giudice MD, PhD[5] | Teresa Lombardi DDS[5]

[1]Department of Medical, Surgical and Health Sciences, University of Trieste, Trieste, Italy

[2]Department of Oral and Maxillofacial Sciences, Sapienza University of Rome, Rome, Italy

[3]Department of Clinical and Experimental Medicine, University of Foggia, Foggia, Italy

[4]Private Practice, Trieste, Italy

[5]Department of Health Sciences, Magna Græcia University, Catanzaro, Italy

Correspondence
Antonio Rapani, Maxillofacial Surgery and Stomatology Clinic Piazza Ospitale, 1-34129 Trieste, Italy.
Email: rapani.antonio@gmail.com

Abstract

Introduction: This study analyzes early marginal bone modifications occurring around platform-switched implants with conical connection placed 1 or 2 mm subcrestally.

Methods: This crossover randomized controlled trial enrolled partially edentulous patients needing two implants in either the posterior maxilla or mandible. Each patient received two platform-switched implants with conical connection inserted 2 mm (Test) and 1 mm (Control) subcrestally. Definitive abutments were immediately connected and, after 4 months of unsubmerged healing, screwed metal-ceramic crowns were delivered. Radiographs were taken at implant placement (T0), prosthesis delivery (T1), and after 1 year of prosthetic loading (T2).

Results: Fifty-one patients (25 males and 26 females; mean age 61.2 ± 12.1 years) totaling 102 implants were included in the final analysis. Mean peri-implant bone level (PBL) reduction from T0 to T2 was not significantly different around Test (0.49 ± 0.32 mm) and Control implants (0.46 ± 0.35 mm; $p = 0.66$). Multivariate linear regression models highlighted a significant positive correlation between history of periodontitis and PBL reduction. At T2, no Test group implant and 6 Control group implants exhibited PBL below the implant platform (11.8% of Control group implants).

Conclusion: No significant differences in peri-implant marginal bone changes were demonstrated after 1 year of prosthetic loading between platform-switched implants with conical connection inserted either 1 or 2 mm subcrestally. However, 2 mm subcrestal placement resulted in deeper implant positioning at T2, with no exposure of treated implant surface and potential preventive effect against subsequent peri-implant pathology.

KEYWORDS

conical connection, early marginal bone loss, peri-implantitis, subcrestal implant placement

This is an open access article under the terms of the Creative Commons Attribution License, which permits use, distribution and reproduction in any medium, provided the original work is properly cited.

© 2023 The Authors. *Clinical Implant Dentistry and Related Research* published by Wiley Periodicals LLC.

SUMMARY BOX

What is known

- Early marginal bone loss (EMBL) is a noninfective peri-implant bone remodeling process with multifactorial etiology and variable entity occurring during the first year of prosthetic loading.
- Recent studies showed a direct correlation between EMBL ≥0.5 mm, late peri-implant bone resorption, and increased probability of future peri-implantitis.
- Subcrestal implant positioning is a clinical strategy to reduce the risk of implant surface exposure due to EMBL.

What this study adds

- Platform-switched implants with conical connection placed 1 or 2 mm subcrestally showed no significant differences in marginal bone remodeling after 1 year of function.
- Deeper subcrestal implant placement (2 mm) resulted in higher peri-implant bone level, with no exposure of treated implant surface and potential preventive effect on future development of peri-implant pathologies.

1 | INTRODUCTION

Peri-implant marginal bone stability has always been considered a crucial factor affecting long-term success of implant therapy. During the first year of function, peri-implant crestal bone undergoes a remodeling process with multifactorial etiology and variable entity. This noninfective process, namely early marginal bone loss (EMBL), is affected by various surgical and prosthetic factors including insufficient bone crest width and/or implant malpositioning,[1–3] excessive surgical trauma,[4,5] supracrestal tissue height adhesion,[6–8] microleakage and bacterial accumulation at the implant-abutment microgap,[9–11] repeated abutment disconnection/reconnections,[12,13] prosthetic abutment height,[14–18] implant-abutment connection mechanical stability[19] and structural bone adaptation to functional loading.[20]

Traditionally, EMBL up to 1.5–2 mm followed by a maximum of 0.2 mm annually thereafter, was commonly observed and considered a defining criterion of implant success.[21–23] The definition of success in implant dentistry has evolved in recent years and EMBL <0.5 mm is currently accepted as a threshold between peri-implant bone physiological stability and a borderline condition potentially favoring subsequent peri-implant pathology.[24–29] EMBL may lead to unwanted treated implant surface exposure to the oral cavity microbiome and surface roughness facilitates bacterial biofilm adhesion, maturation, and colonization. Recent studies demonstrated a direct correlation between EMBL ≥0.5 mm, late peri-implant bone resorption, and increased probability of future peri-implantitis.[24,27,28]

Subcrestal implant positioning is a clinical strategy to reduce the risk of implant surface exposure due to EMBL. According to Linkevicius and coworkers, when the implant platform is positioned subcrestally, EMBL may occur either only above the implant neck (bone remodeling) or may also involve bone surrounding the implant neck and underlying implant surface (bone loss).[30] Counteracting marginal bone modification by adapting the vertical position of the implant may limit EMBL to bone remodeling, avoiding treated implant surface exposure.[31,32]

However, controversial information is present in literature regarding the relationship between marginal bone stability and subcrestal implant placement. Some authors observed that implant placement 1 or 2 mm subcrestally is associated with minimal marginal bone modification,[33,34] whereas other investigators demonstrated that EMBL is directly associated with implant insertion depth.[35,36] Comparative studies showed that subcrestal implant placement negatively influenced peri-implant bone stability when compared with equicrestal positioning.[37–39] In a recent meta-analysis, Valles et al.[40] concluded that platform-switched implants placed subcrestally exhibit less marginal bone change than implants placed equicrestally. Among study limitations, however, these last authors highlighted that only few clinical trials with low numbers of patients and high risk of bias were included in the meta-analysis. Moreover, significant heterogeneity was present between the selected studies. This fact was likely responsible for the different results reported in the included investigations. These authors encouraged further well-designed trials with adequate sampling and longer follow-up to confirm the tendency expressed in their meta-analysis.

Therefore, the present crossover randomized controlled trial analyzes marginal bone changes occurring around implants with platform-switching and conical connection placed subcrestally at different depths (1 vs. 2 mm) and closely followed for 1 year after prosthetic loading.

2 | MATERIALS AND METHODS

2.1 | Study design

This study is a multicenter, crossover randomized controlled trial, reported following CONSORT (CONsolidated Standards of Reporting

17088208, 2023, 2, Downloaded from https://onlinelibrary.wiley.com/doi/10.1111/cid.13186 by CochraneItalia, Wiley Online Library on [15/04/2024]. See the Terms and Conditions (https://onlinelibrary.wiley.com/terms-and-conditions) on Wiley Online Library for rules of use; OA articles are governed by the applicable Creative Commons License

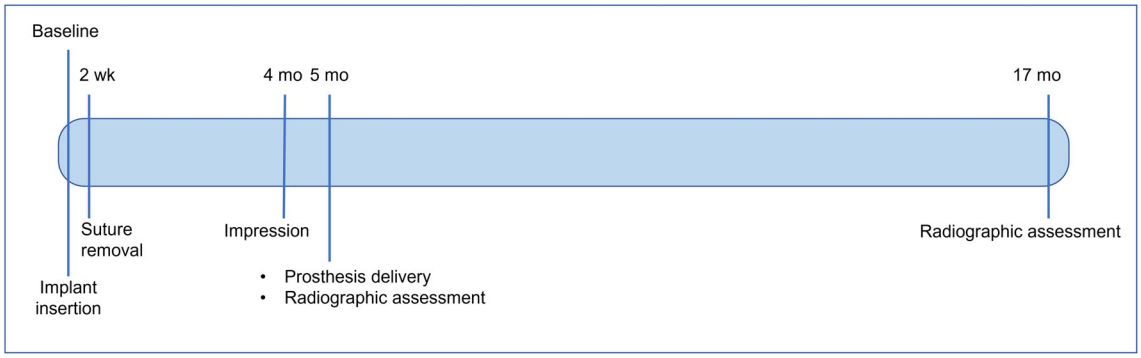

FIGURE 1 Flow chart of time points for data collection.

Trials) guidelines. Patients were enrolled and treated by five experienced operators from May 2020 to March 2021. The study protocol was designed in accordance with recommendations expressed in the Helsinki Declaration for investigations on human subjects (as revised in Fortaleza 2013). The study protocol was approved by the relevant ethical committee (Comitato Etico Regione Calabria – Sezione Area Centro no. 369/2020) and retrospectively recorded in a public registry of clinical trials (www.clinicaltrials.gov—NCT05494476). Researchers from different clinical centers attended a calibration meeting prior to the study to standardize operative protocols and data collection in order to improve interexaminer consistency. All patients were thoroughly informed regarding the study protocol, the therapeutic project and its alternatives and related risks. Each patient signed a written informed consent and authorized the use of his/her data for research purposes.

The present trial tested the null hypothesis of no difference in marginal bone remodeling after 1 year of function around subcrestal implants inserted at different depths (2 mm subcrestally [Test] and 1 mm subcrestally [Control]), against the alternative hypothesis of a difference. The flow chart of time points for data collection is summarized in Figure 1.

2.2 | Patient selection

All patients with partial edentulism (Kennedy Class I or II)[41] needing two implants in either the posterior maxilla or posterior mandible were screened for potential recruitment into the present trial.

General inclusion criteria were: (i) age > 18 years; (ii) good general health; (iii) absence of systemic disease affecting bone metabolism and wound healing; (iv) patient willingness and ability to follow the study protocol; (v) signed written informed consent.

Local inclusion criteria were: (i) bone crest width ≥6 mm at implant site; (ii) available bone height ≥9 mm at implant site; (iii) absence of regenerated bone; (iv) healed bone crest (at least 6 months after tooth loss/extraction); (v) buccolingual width of keratinized mucosa at implant site ≥4 mm; (vi) vertical mucosal thickness at implant site ≥2.5 mm; (vii) full mouth plaque score <25% and full mouth bleeding score <20%.

Exclusion criteria were: (i) absolute general contraindications to implant surgery[42]; (ii) poorly controlled diabetes (HBA1c > 7.5%); (iii) present or past treatment with antiresorptives; (iv) radiotherapy in the head and/or neck area in the last 5 years; (v) pregnancy; (vi) untreated periodontal disease; (vii) substance abusers; (viii) low implant primary stability (implant stability quotient <50); (ix) implant insertion torque (IT) >60 Ncm.

The following patient-level information was collected: age, gender, systemic disease, medication, smoking habit (yes/no), and history of periodontal disease (patients with at least three sites with probing depth ≥5 mm, who had received either nonsurgical or surgical periodontal therapy and/or dental extraction for periodontal reasons).

All patients received professional deplaquing and oral hygiene instruction 1 week prior to implant surgery.

2.3 | Surgical and restorative procedures

Pre-treatment antibiotic prophylaxis was administered 1 h prior to implant surgery (amoxicillin 2 g). Under local anesthesia, an incision along the center of the ridge was performed. After elevating a mucoperiosteal buccal envelope flap, vertical thickness of the supracrestal mucosa of the undetached lingual flap was measured at implant sites using a soft-tissue probe (SSL, Medesy, Maniago, Italy). If vertical mucosal thickness was ≥2.5 mm, an independent investigator opened the randomization envelope and communicated the assigned treatment to the surgeon. After performing implant site preparation following manufacturer's instructions, two 4.0 mm diameter implants with platform switching and conical hybrid connection (5°; AnyRidge, MegaGen, Gyeongbuk, South Korea) were inserted 2 mm (Test) and 1 mm (Control) subcrestally, recording IT values with the surgical motor (Implantmed, W&H, Burmoos, Austria). The selected titanium implant surface (Grade 4), designed for subcrestal positioning, is fully sandblasted, large grit, and acid-etched with calcium ions incorporated (Xpeed, MegaGen, Gyeongbuk, South Korea). A security distance of 3.0 mm between implants and 1.5 mm from adjacent teeth was kept. Implants were immediately connected to 3 mm high, straight, *trans*-epithelial abutments (Octa, MegaGen, Gyeongbuk, South Korea),

17088208, 2023, 2, Downloaded from https://onlinelibrary.wiley.com/doi/10.1111/cid.13186 by CochraneItalia, Wiley Online Library on [15/04/2024]. See the Terms and Conditions (https://onlinelibrary.wiley.com/terms-and-conditions) on Wiley Online Library for rules of use; OA articles are governed by the applicable Creative Commons License

which were tightened to 30 Ncm and covered with healing caps. Flaps were then sutured around *trans*-epithelial abutments for unsubmerged healing with single stitches and using the Sentineri technique with synthetic monofilament.[43] Antibiotics were prescribed for 5 days (amoxicillin/clavulanate 1 g twice a day) and ibuprofen 600 mg when needed.

Sutures were removed after 10 days. No removable prostheses were used during the entire healing period. After 4 months, abutment-level impressions were taken and metal-ceramic prostheses (splinted crowns (SCs) or implant bridge [IB]) screwed to the *trans*-epithelial abutments were manufactured. Patients were recalled 4, 8, and 12 months after prosthesis delivery for clinical examination and maintenance visit.

2.4 | Radiographic measurements

Periapical radiographs were performed using paralleling technique with a Rinn-type positioner, customized for each patient with bite jig, at implant placement (Baseline, T0), prosthetic restoration delivery (T1), and after 12 months of prosthetic loading (T2; Figure 2). All radiographs were performed using the same device (FOCUS, KaVo, Biberach, Germany), with the same setting (60 kV, 7 mA).

Peri-implant bone levels (PBL) were measured at each time point as the linear distance between implant platform and bone crest at mesial and distal aspects of each implant. A positive value was assigned if the bone crest was coronal to the implant platform, whereas a negative value was assigned if the first bone-to-implant contact was apical to the implant platform. Measurements were calibrated referring to the known implant diameter at platform level (Figure 3). Each radiograph showing deformation, darkness, and/or other problems was immediately repeated. All measurements were performed by two examiners (Antonio Rapani and Claudio Stacchi), using measuring software (Image J 1.52a, National Institutes of Health, Bethesda, Maryland) on a 24-inch medical grade monitor. Each measurement was performed three times at three different time points as proposed by Gomez-Roman and Launer.[44] Examiner calibration was performed on a sample of 10 radiographs not included in the study. Cohen's *k* coefficient was calculated by a third author (Giuseppe Troiano): intraexaminer and interexaminer agreement was 87.4% and 82.8%, respectively, for linear measurements within ±0.1 mm.

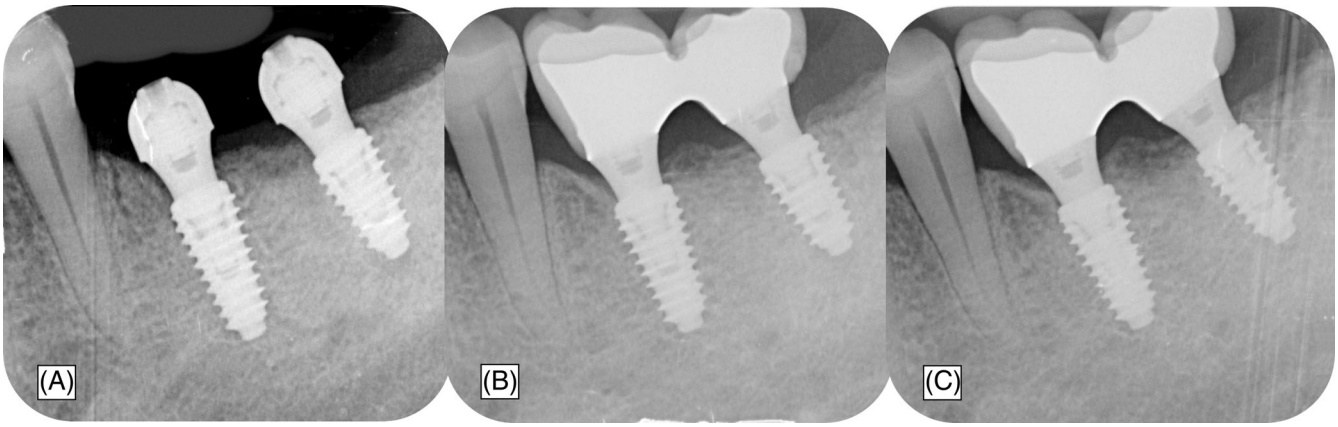

FIGURE 2 Periapical radiographs were performed at implant placement (A), prosthetic restoration delivery (B), and after 12 months of prosthetic loading (C).



FIGURE 3 Measurements on mesial (zm; ym) and distal aspect (zd; yd) of each implant were calculated using specific software (Image J 1.52a). Calibration was performed referring to the known implant diameter at platform level (x).

17088208, 2023, 2, Downloaded from https://onlinelibrary.wiley.com/doi/10.1111/cid.13186 by CochraneItalia, Wiley Online Library on [15/04/2024]. See the Terms and Conditions (https://onlinelibrary.wiley.com/terms-and-conditions) on Wiley Online Library for rules of use; OA articles are governed by the applicable Creative Commons License

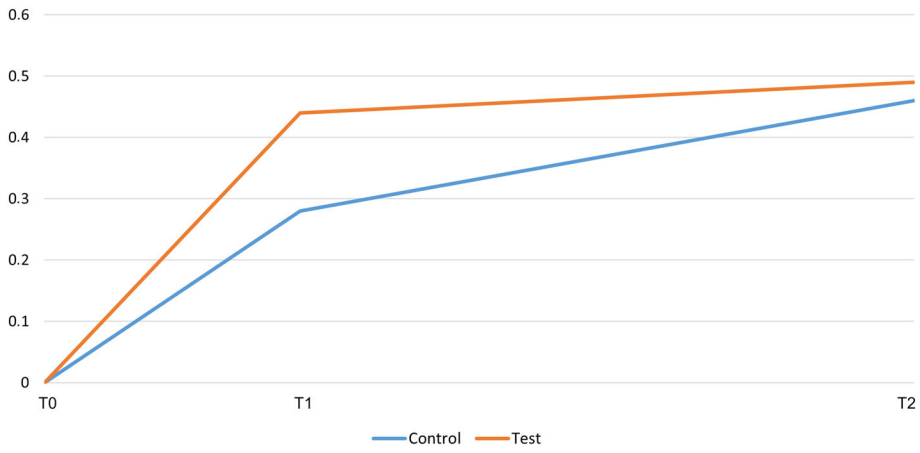

FIGURE 4 Pattern of peri-implant bone-level reduction (expressed in mm) in the two groups. T0, implant insertion; T1, prosthesis delivery; T2, 1 year of loading.

2.5 | Predictor and outcome variables

The primary predictor variable was implant insertion depth (1 vs. 2 mm subcrestally).

Primary outcome measure:

- EMBL up to 1 year of function.

Secondary outcome measures:

- exposure of treated implant surface;
- any complication or adverse event.

2.6 | Sample size and randomization

Sample size was calculated using web-based software (https://app.sampsize.org.uk). Effect size was calculated based on the difference in MBL after 1 year of function around platform-switched implants with conical connection placed 1 or 2 mm subcrestally reported in a previous study (mean and SD of two groups: 0.69 ± 0.40 and 1.07 ± 0.65).[36] A minimum sample of 48 patients (96 implants) was necessary to detect significant difference (confidence level 5% with a statistical power of 90%). To compensate possible dropouts, it was planned to enroll 55 patients (110 implants).

An independent investigator (Giuseppe Troiano), not involved in treatment of patients, prepared a computer-generated table using a balanced, randomly permuted block approach (www.random.org), assigning the two implants of each patient to the different groups (Test and Control). Randomization codes were enclosed in numbered, identical, sealed, opaque envelopes. Envelopes were opened after flap reflection. Treatment allocation was concealed to the operators in charge of enrolling and treating the patients of this trial.

2.7 | Statistical analysis

An independent investigator (Giuseppe Troiano.) performed data analysis using STATA 16.0 software (StataCorp, College Station, Texas). Descriptive statistics were calculated as frequencies for categorical variables and mean with standard deviations for continuous variables. Assessment of normal distribution in the assessed outcomes at different time points was performed by means of Shapiro–Wilk test. Differences between continuous variables between the two groups (Test and Control) were assessed with a *t*-test for parametric data and with a two-sample Wilcoxon rank-sum test for nonparametric data, whereas the χ^2 test was used to evaluate categorical variables. Multivariate linear regression models were built to assess the influence of different variables on EMBL at different time points.

3 | RESULTS

A total of 94 consecutive patients were screened for eligibility and 55 patients fulfilled selection criteria and were enrolled in this study. Four patients did not present at T1 due to coronavirus disease 2019 limitations and dropped out of the trial (prosthetic treatment of these patients was successfully completed later). Fifty-one patients (25 males and 26 females; age range 36–87 years, mean 61.2 ± 12.1 years; 12 smokers, 39 nonsmokers; 15 with history of periodontitis, 36 with no history of periodontitis) were included in the final analysis. Each patient received 2 implants in the posterior maxilla or posterior mandible (maxilla = 54 implants; mandible = 48 implants; total = 102 implants). Surgical and prosthodontic treatment was conducted by five experienced clinicians (CS $n = 11$ patients; LL, $n = 10$ patients; MM, $n = 9$ patients; AG, $n = 10$ patients; TL, $n = 11$ patients).

Four months after placement, all 102 implants resulted osseointegrated and abutment-level impressions were taken for subsequent prosthetic rehabilitation. Patients received screwed metal-ceramic SCs ($n = 54$) and screwed metal-ceramic IBs (n = 48). Patients were followed for 12 months after prosthetic loading. At the last follow-up, all 102 implants were satisfactorily in function, with no evidence of local biological or mechanical complications or systemic side effects.

Mean PBL measured at each time point at both the mesial and distal aspect of the fixture were compared using a two-sample Wilcoxon rank-sum test. No significant differences were found in either Test or Control group at T0 (Test: p = 0.45; Control: $p = 0.54$),

17088208, 2023, 2, Downloaded from https://onlinelibrary.wiley.com/doi/10.1111/cid.13186 by CochraneItalia, Wiley Online Library on [15/04/2024]. See the Terms and Conditions (https://onlinelibrary.wiley.com/terms-and-conditions) on Wiley Online Library for rules of use; OA articles are governed by the applicable Creative Commons License

T1 (Test: p = 0.72; Control: p = 0.70), and T2 (Test: $p = 0.09$; Control: $p = 0.76$). Therefore, mean value between mesial and distal PBL was used in the subsequent analyses. Additionally, a one-way ANOVA test was performed to assess center effect, using the clinical center as grouping variable and PBL at T0, T1, and T2 as dependent variables. Results showed no significant difference in PBL at different time points among the different operators ($p = 0.74$).

At Baseline (T0), mean subcrestal positioning was 1.93 ± 0.43 and 1.06 ± 0.36 mm in Test and Control group, respectively. At prosthesis delivery (T1), mean PBL reduction was 0.44 ± 0.30 mm and 0.28 ± 0.32 mm in Test and Control group, respectively. Two-sample Wilcoxon rank-sum test demonstrated that PBL reduction from T0 to T1 was significantly higher in Test than in Control group ($p = 0.005$). After 1 year of prosthetic loading (T2), further slight PBL reduction (mean 0.05 ± 0.25 mm) was recorded in Test group, whereas Control group implants exhibited an additional mean PBL reduction of 0.18 ± 0.25 mm. The two-sample Wilcoxon rank-sum test demonstrated that PBL reduction from T1 to T2 was significantly lower in Test than in Control group ($p = 0.001$). PBL reduction pattern in the two groups is graphically presented in Figure 4. At T2, mean subcrestal positioning was 1.44 ± 0.50 and 0.60 ± 0.43 mm in Test and Control group,

TABLE 1 Multivariate analysis of variables potentially influencing PBL from T0 to T1.

Number of cases = 102 PBL T1–T0	Multivariate analysis		
	Coefficient	[95% CI]	*p*-Value
Surgical Site			
Maxilla	1.		
Mandible	0.08	[−0.04 to 0.21]	0.203
History of periodontitis			
No	1.		
Yes	−0.19	[−0.35 to 0.03]	0.022*
Smoking			
No	1.		
Yes	−0.07	[−0.24 to 0.10]	0.416
Subcrestal positioning			
1 mm	1.		
2 mm	−0.16	[−0.28 to 0.04]	0.007*

Abbreviations: CI, confidence interval; PBL, peri-implant bone level; T0, implant insertion; T1, prosthesis delivery.
*Statistical significance ($p < 0.05$).

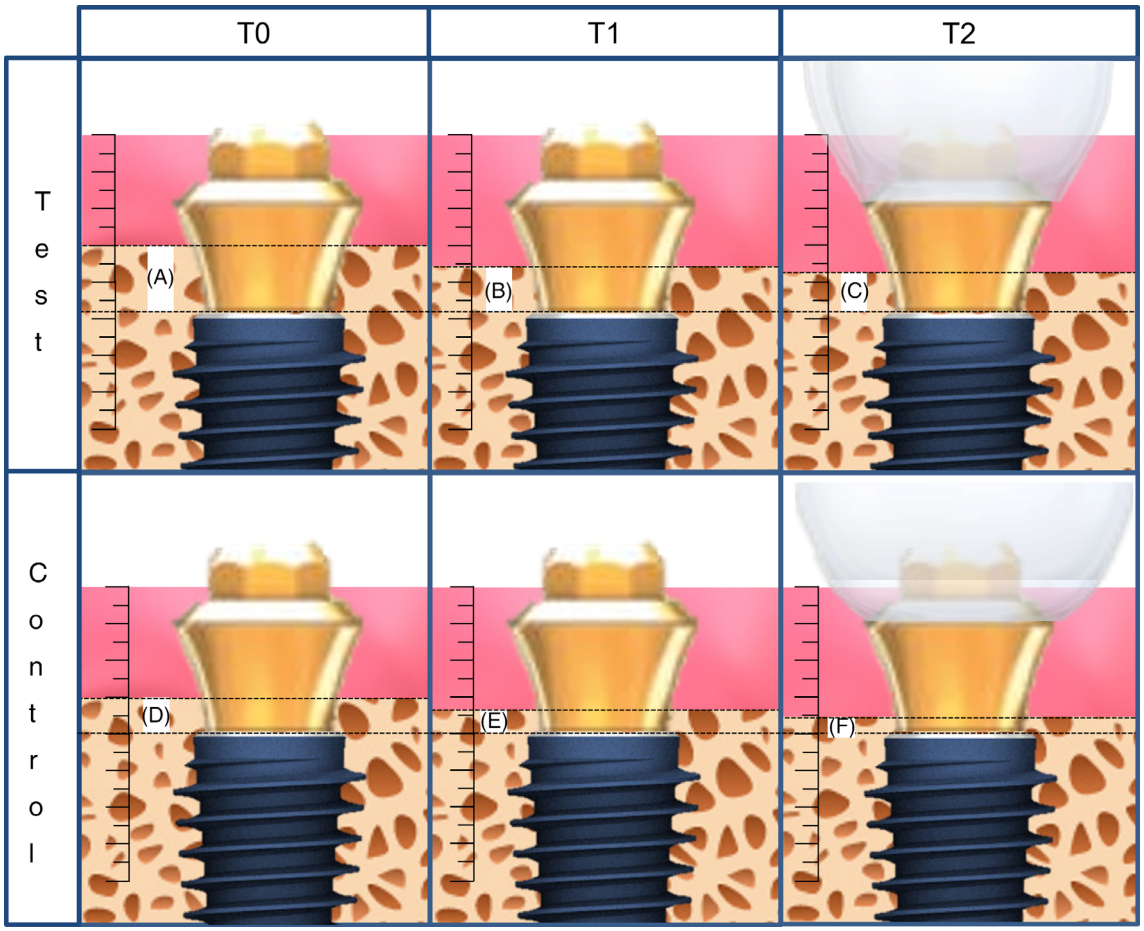

FIGURE 5 Mean peri-implant bone levels at implant insertion (T0), prosthesis delivery (T1), and after 1 year of loading (T2) in test and control groups. (A) 1.93 ± 0.43 mm; (B) 1.49 ± 0.47 mm; (C) 1.44 ± 0.50 mm; (D) 1.06 ± 0.36 mm; (e) 0.79 ± 0.44 mm; (F) 0.60 ± 0.43 mm.

17088208, 2023, 2, Downloaded from https://onlinelibrary.wiley.com/doi/10.1111/cid.13186 by CochraneItalia, Wiley Online Library on [15/04/2024]. See the Terms and Conditions (https://onlinelibrary.wiley.com/terms-and-conditions) on Wiley Online Library for rules of use; OA articles are governed by the applicable Creative Commons License

TABLE 2 Multivariate analysis of variables potentially influencing PBL from T1 to T2.

Number of cases = 102 PBL T2–T1	Multivariate analysis		
	Coefficient	[95% CI]	*p*-Value
Surgical site			
Maxilla	1.		
Mandible	0.03	[−0.08 to 0.14]	0.635
History of periodontitis			
No	1.		
Yes	−0.01	[−0.16 to 0.13]	0.871
Smoking			
No	1.		
Yes	0.02	[−0.12 to 0.17]	0.750
Subcrestal positioning			
1 mm	1.		
2 mm	0.13	[0.03 to 0.23]	0.014*
Prosthesis			
SC	−0.01	[−0.12 to 0.10]	0.830
IB	−0.05	[−0.44 to 0.33]	0.778

Abbreviations: CI, confidence interval; IB, implant bridge; PBL, Peri-implant bone level; SC, splinted crown; T1, prosthesis delivery; T2, 1 year of loading.
*Statistical significance ($p < 0.05$).

TABLE 3 Multivariate analysis of variables potentially influencing PBL from T2 to T0.

Number of cases = 102 PBL T2–T0	Multivariate analysis		
	Coefficient	[95% CI]	*p*-Value
Surgical site			
Maxilla	1.		
Mandible	0.11	[−0.02 to 0.25]	0.105
History of periodontitis			
No	1.		
Yes	−0.24	[−0.42 to −0.06]	0.011*
Smoking			
No	1.		
Yes	−0.03	[−0.21 to 0.15]	0.722
Subcrestal positioning			
1 mm	1.		
2 mm	−0.03	[−0.16 to 0.09]	0.591
Prosthesis			
SC	0.07	[−0.06 to 0.20]	0.289
IB	0.09	[−0.39 to 0.57]	0.710

Abbreviations: CI, confidence interval; IB, implant bridge; PBL, peri-implant bone level; SC, splinted crown; T0, Implant insertion; T2, 1 year of loading.
*Statistical significance ($p < 0.05$).

respectively, with six Control group implants exhibiting PBL below the implant platform (11.8% of Control group implants). Total mean PBL reduction (T0-T2) was 0.49 ± 0.32 mm around Test implants and 0.46 ± 0.35 mm around Control implants, with no significant differences between the two groups ($p = 0.66$). PBL resorption pattern in the two groups is depicted in Figure 5.

Multivariate analysis highlighted a significant positive correlation between history of periodontitis and PBL reduction from T0 to T1 ($p = 0.02$) and from T0 to T2 ($p = 0.01$). Implant placement depth showed a significant positive correlation from T0 to T1 ($p = 0.007$) and a significant negative correlation from T1 to T2 ($p = 0.014$) with PBL reduction. Complete results of multivariate analysis are listed in Tables 1–3.

4 | DISCUSSION

This multicenter crossover randomized controlled trial compares marginal bone changes occurring around platform-switched conical connection implants placed subcrestally at different depths (1 vs. 2 mm). The design of this study aimed to control variables influencing EMBL, in order to highlight the effect of implant positioning depth on marginal bone stability. The crossover design minimized the influence of patient-related confounding factors because all interventions were performed on and measurements taken from the same participants. Two implants were placed in each patient, selecting sites with similar bone density (upper or lower premolar and molar area). Implant site preparation was performed by experienced clinicians after a calibration session held prior to the study. Most clinical variables potentially influencing EMBL were controlled in the study protocol (site-related factors [crestal bone width ≥6 mm[1–3]; mucosal thickness ≥2.5 mm[8,45]; keratinized mucosal band width ≥4 mm[46,47]], surgical-related factors [bone overheating[48] and excessive implant IT[5,49]] and prosthetic factors [platform-switched conical connection[19,50]; 3 mm high prosthetic abutment[14–16]; one abutment-one time protocol[12,13]; and screwed prosthetic retention[51,52]]).

In this study, mean PBL reduction after 1 year of prosthetic loading was not significantly different between the two groups (Test: 0.49 ± 0.32 mm; Control: 0.46 ± 0.35 mm; $p = 0.66$). This outcome is in accordance with previous clinical studies comparing platform-switched conical connection implants restored with a one abutment-one time protocol and inserted at different subcrestal depths.[35,53]

However, it is interesting to note that peri-implant bone remodeling occurred with different patterns in the two groups. At T1, after 5 months of unsubmerged healing, Test implants lost significantly more bone than Control implants (0.44 ± 0.30 and 0.28 ± 0.32 mm; $p = 0.005$). This finding is consistent with numerous clinical studies showing greater bone remodeling related to supracrestal tissue height establishment when an implant is placed in a deeper subcrestal position.[8,35,53–55]

Conversely, marginal bone remodeling was significantly higher in Control group than in Test group during the first year of functional loading (0.18 ± 0.25 and 0.05 ± 0.25 mm; $p = 0.001$). A different distribution of loading forces to peri-implant bone may be advocated to explain this finding. At prosthesis delivery (T1), mean subcrestal

17088208, 2023, 2, Downloaded from https://onlinelibrary.wiley.com/doi/10.1111/cid.13186 by CochraneItalia, Wiley Online Library on [15/04/2024]. See the Terms and Conditions (https://onlinelibrary.wiley.com/terms-and-conditions) on Wiley Online Library for rules of use; OA articles are governed by the applicable Creative Commons License

positioning of implant platform was 1.49 ± 0.47 mm in Test group and 0.79 ± 0.44 mm in Control group. Considering mean cortical thickness in human jaws (1.07 ± 0.44 mm in the posterior mandible and 0.71 ± 0.27 mm in the posterior maxilla[56]), at T1 the implant-abutment junction was likely positioned at cortical level in Control group and subcortically in Test group. Finite element analyses showed that subcrestal placement decreases stress in the crestal cortical bone.[57] In particular, equicrestal implants showed maximum von Mises stresses, followed by 1 mm subcrestal implants and then 2 mm subcrestal implants.[58,59] Bone remodeling is regulated by different bone cells, such as osteocytes and bone lining cells (BLCs), constituting a functional syncytium with mechano-receptive activity. Under functional loading, molecular signals from osteocytes and BLC regulate the interplay of bone formation and resorption.[60] The cortical layer is mechanically more sensitive than spongious bone.[61,62] Greater bone remodeling occurring in Control group after prosthetic loading may be the result of higher mechanical sensitivity of the bone surface compared with the inner regions of bone.[63,64]

Moreover, Control group implants presented a shorter mucosal tunnel than Test group implants. Mucosal tunnel depth plays a critical role in determining restorative design. A limited vertical distance between prosthetic platform and gingival margin may result in overcontoured restorations.[18] Even if clinical studies and systematic reviews[65,66] found a correlation between wide emergence angle, convex restoration contour, and peri-implantitis, the direct association between these factors and EMBL is still to be elucidated. Recent studies showed contradictory results. Lops et al.[67] found that PBL does not seem to be affected by wide emergence angle for platform-switched implants with a stable internal conical connection, whereas Strauss et al.[68] suggested that a restorative angle <40° may limit EMBL.

At T2, 6 Control group implants exhibited PBL below the implant platform (11.8% of Control group implants), whereas no early implant surface exposure was recorded in Test group. This outcome, consistent with previous studies,[8,35,53,69] suggests that 2 mm subcrestal positioning could be beneficial in terms of preventing further MBL[24] and future onset of peri-implantitis.[27,28]

Moreover, Test implants resulted in a significant more subcrestal position at T2, when compared with Control implants (1.44 ± 0.50 and 0.60 ± 0.43 mm, respectively). This finding could have a positive effect, as the presence of bone coronal to the implant platform can be regarded as a form of biological shield preventing unwanted bacterial colonization of the treated implant surface. On the other hand, deeper mucosal tunnels may reduce the efficacy of bacterial biofilm removal during home oral care procedures and professional maintenance recalls.[70] A recent case-control study reported that deep mucosal tunnels may delay the resolution of experimental peri-implant mucositis when compared with shallow mucosal tunnels.[71] However, long-term studies conducted on large samples are needed to evaluate the real clinical significance of this aspect in influencing the onset of peri-implant pathologies.

Multivariate analysis showed a significant positive correlation between history of periodontitis and PBL reduction from T0–T1 to T0–T2, in accordance with numerous previous studies.[29,72,73] It is interesting to observe how the effect of history of periodontitis is not significant from T1 to T2, when prosthetic factors start to influence EMBL. This is in close agreement with a recent study by Galindo-Moreno et al.,[29] showing that EMBL follows different patterns in periodontal patients, being conditioned by abutment height. In particular, periodontal patients with implants restored with long abutments, like happened in this study, lose very few marginal bone over time. Some limitations should be considered when interpreting the findings of the present multicenter crossover randomized controlled trial. Factors including the selection of surgical sites in specific areas (only posterior maxilla and mandible) with specific characteristics (medium-thick mucosal thickness, 4 mm keratinized tissue band) and the use of a single implant type with specific characteristics[74] should be carefully considered. Therefore, the present results cannot be automatically generalized to different clinical situations. Furthermore, the use of peri-apical radiographs to assess marginal bone level represents another limitation. This approach does not allow the evaluation of buccal and lingual aspects of peri-implant bone, reducing sensitivity in detecting marginal bone changes.

The null hypothesis of this trial could not be rejected from the data of this study. Within the aforementioned limitations, no significant difference in peri-implant marginal bone remodeling was demonstrated after 1 year of functional loading between platform-switched conical connection implants inserted 1 or 2 mm subcrestally. However, deeper subcrestal implant placement (2 mm) resulted in higher PBL at T2, with no exposure of treated implant surface and potential preventive effect on future development of peri-implant pathologies.

AUTHOR CONTRIBUTIONS

Claudio Stacchi: Concept/Design, data collection, data analysis/interpretation, drafting article, and approval of article. **Luca Lamazza:** Data collection, drafting article, and approval of article. **Antonio Rapani:** Data collection, critical revision of article, and approval of article. **Giuseppe Troiano:** Statistics, data analysis/interpretation, drafting article, and approval of article. **Marcello Messina:** Data collection, critical revision of article, and approval of article. **Alessandro Antonelli:** Data collection, critical revision of article, and approval of article. **Amerigo Giudice:** Data collection, critical revision of article, and approval of article. **Teresa Lombardi:** Concept/design, data collection, data analysis/interpretation, drafting article, and approval of article.

ACKNOWLEDGMENTS

This study was self-funded. The Authors wish to thank Richard de Roeck for linguistic revision. Open Access Funding provided by Universita degli Studi di Trieste within the CRUI-CARE Agreement.

CONFLICT OF INTEREST STATEMENT

The authors declare no conflict of interest.

DATA AVAILABILITY STATEMENT

The data that support the findings of this study are available on request from the corresponding author. The data are not publicly available due to privacy or ethical restrictions.

17088208, 2023, 2, Downloaded from https://onlinelibrary.wiley.com/doi/10.1111/cid.13186 by CochraneItalia, Wiley Online Library on [15/04/2024]. See the Terms and Conditions (https://onlinelibrary.wiley.com/terms-and-conditions) on Wiley Online Library for rules of use; OA articles are governed by the applicable Creative Commons License

ORCID

Claudio Stacchi https://orcid.org/0000-0003-4017-4980
Luca Lamazza https://orcid.org/0000-0002-4395-116X
Antonio Rapani https://orcid.org/0000-0002-9767-4401
Giuseppe Troiano https://orcid.org/0000-0001-5647-4414
Amerigo Giudice https://orcid.org/0000-0002-5091-6979

REFERENCES

1. Spray JR, Black CG, Morris HF, Ochi S. The influence of bone thickness on facial margin bone response: stage 1 placement through stage 2 uncovering. *Ann Periodontol*. 2000;5(1):119-128.
2. Grunder U, Gracis S, Capelli M. Influence of 3-D bone-to-implant relationship on esthetics. *Int J Periodontics Restorative Dent*. 2005;25(2):113-119.
3. Chen ST, Darby IB, Reynolds EC. A prospective clinical study of non-submerged immediate implants: clinical outcomes and esthetic results. *Clin Oral Implants Res*. 2007;18(5):552-562.
4. Albrektsson T, Chrcanovic B, Östman PO, Sennerby L. Initial and long-term crestal bone responses to modern dental implants. *Periodontol 2000*. 2017;73(1):41-50.
5. Coyac BR, Leahy B, Salvi G, Hoffmann W, Brunski JB, Helms JA. A preclinical model links Osseo-densification due to misfit and Osseo-destruction due to stress/strain. *Clin Oral Implants Res*. 2019;30(12):1238-1249.
6. Hermann JS, Buser D, Schenk RK, Cochran DL. Crestal bone changes around titanium implants. A histometric evaluation of unloaded non-submerged and submerged implants in the canine mandible. *J Periodontol*. 2000;71(9):1412-1424.
7. Hermann JS, Buser D, Schenk RK, Higginbottom FL, Cochran DL. Biologic width around titanium implants. A physiologically formed and stable dimension over time. *Clin Oral Implants Res*. 2000;11(1):1-11.
8. Spinato S, Bernardello F, Lombardi T, et al. Influence of apico-coronal positioning of tissue-level implants on marginal bone stability during supracrestal tissue height establishment: a multi-centre prospective study. *Clin Implant Dent Relat Res*. 2022;24(5):611-620.
9. Ericsson I, Berglundh T, Marinello C, Lindhe J. Long-standing plaque, gingivitis at implants and teeth in dogs. *Clin Oral Implants Res*. 1992;3(3):99-103.
10. Jansen VK, Conrads G, Richter EJ. Microbial leakage and marginal fit of the implant-abutment interface. *Int J Oral Maxillofac Implants*. 1997;12(4):527-540.
11. Piattelli A, Vrespa G, Petrone G, Iezzi G, Annibali S, Scarano A. Role of the microgap between implant and abutment: a retrospective histologic evaluation in monkeys. *J Periodontol*. 2003;74(3):346-352.
12. Tallarico M, Caneva M, Meloni SM, Xhanari E, Covani U, Canullo L. Definitive abutments placed at implant insertion and never removed: is it an effective approach? A systematic review and meta-analysis of randomized controlled trials. *J Oral Maxillofac Surg*. 2018;76(2):316-324.
13. Vatėnas I, Linkevičius T. One abutment one time vs. repeatable abutment disconnections in implants, restored with cemented / screw retained fixed partial dentures: marginal bone level changes. A systematic review and meta-analysis. *Stomatologija*. 2021;23(2):35-40.
14. Galindo-Moreno P, León-Cano A, Ortega-Oller I, et al. Prosthetic abutment height is a key factor in peri-implant marginal bone loss. *J Dent Res*. 2014;93(7 Suppl):80S-85S.
15. Blanco J, Pico A, Caneiro L, Nóvoa L, Batalla P, Martín-Lancharro P. Effect of abutment height on interproximal implant bone level in the early healing: a randomized clinical trial. *Clin Oral Implants Res*. 2018;29(1):108-117.
16. Spinato S, Stacchi C, Lombardi T, Bernardello F, Messina M, Zaffe D. Biological width establishment around dental implants is influenced by abutment height irrespective of vertical mucosal thickness: a cluster randomized controlled trial. *Clin Oral Implants Res*. 2019;30(7):649-659.
17. Spinato S, Stacchi C, Lombardi T, et al. Influence of abutment height and vertical mucosal thickness on early marginal bone loss around implants. A randomized clinical trial with an 18-month post-loading clinical and radiographic evaluation. *Int J Oral Implantol (Berl)*. 2020;13(3):279-290.
18. Saleh MH, Galli M, Siqueira R, Vera M, Wang HL, Ravidà A. The prosthetic-biologic connection and its influence on peri-implant health: an overview of the current evidence. *Int J Oral Maxillofac Implants*. 2022;37(4):690-699.
19. Liu Y, Wang J. Influences of microgap and micromotion of implant-abutment interface on marginal bone loss around implant neck. *Arch Oral Biol*. 2017;83:153-160.
20. Oh TJ, Yoon J, Misch CE, Wang HL. The causes of early implant bone loss: myth or science? *J Periodontol*. 2002;73(3):322-333.
21. Adell R, Lekholm U, Rockler B, Brånemark PI. A 15-year study of osseointegrated implants in the treatment of the edentulous jaw. *Int J Oral Surg*. 1981;10(6):387-416.
22. Albrektsson T, Zarb G, Worthington P, Eriksson AR. The long-term efficacy of currently used dental implants: a review and proposed criteria of success. *Int J Oral Maxillofac Implants*. 1986;1(1):11-25.
23. Smith DE, Zarb GA. Criteria for success of osseointegrated endosseous implants. *J Prosthet Dent*. 1989;62(5):567-572.
24. Galindo-Moreno P, León-Cano A, Ortega-Oller I, Monje A, O'Valle F, Catena A. Marginal bone loss as success criterion in implant dentistry: beyond 2 mm. *Clin Oral Implants Res*. 2015;26(4):e28-e34.
25. Derks J, Schaller D, Håkansson J, Wennström JL, Tomasi C, Berglundh T. Effectiveness of implant therapy analyzed in a Swedish population: prevalence of peri-implantitis. *J Dent Res*. 2016;95(1):43-49.
26. Derks J, Schaller D, Håkansson J, Wennström JL, Tomasi C, Berglundh T. Peri-implantitis - onset and pattern of progression. *J Clin Periodontol*. 2016;43(4):383-388.
27. Windael S, Vervaeke S, Wijnen L, Jacquet W, De Bruyn H, Collaert B. Ten-year follow-up of dental implants used for immediate loading in the edentulous mandible: a prospective clinical study. *Clin Implant Dent Relat Res*. 2018;20(4):515-521.
28. Windael S, Collaert B, De Buyser S, De Bruyn H, Vervaeke S. Early peri-implant bone loss as a predictor for peri-implantitis: a 10-year prospective cohort study. *Clin Implant Dent Relat Res*. 2021;23(3):298-308.
29. Galindo-Moreno P, Catena A, Pérez-Sayáns M, Fernández-Barbero JE, O'Valle F, Padial-Molina M. Early marginal bone loss around dental implants to define success in implant dentistry: a retrospective study. *Clin Implant Dent Relat Res*. 2022;24(5):630-642.
30. Linkevicius T, Puisys A, Linkevicius R, Alkimavicius J, Gineviciute E, Linkeviciene L. The influence of submerged healing abutment or subcrestal implant placement on soft tissue thickness and crestal bone stability. A 2-year randomized clinical trial. *Clin Implant Dent Relat Res*. 2020;22(4):497-506.
31. Vervaeke S, Matthys C, Nassar R, Christiaens V, Cosyn J, De Bruyn H. Adapting the vertical position of implants with a conical connection in relation to soft tissue thickness prevents early implant surface exposure: a 2-year prospective intra-subject comparison. *J Clin Periodontol*. 2018;45(5):605-612.
32. Doornewaard R, De Bruyn H, Matthys C, Bronkhorst E, Vandeweghe S, Vervaeke S. The long-term effect of adapting the vertical position of implants on peri-implant health: a 5-year intra-subject comparison in the edentulous mandible including oral health-related quality of life. *J Clin Med*. 2020;9(10):3320.
33. Donovan R, Fetner A, Koutouzis T, Lundgren T. Crestal bone changes around implants with reduced abutment diameter placed non-submerged and at subcrestal positions: a 1-year radiographic evaluation. *J Periodontol*. 2010;81(3):428-434.

17088208, 2023, 2, Downloaded from https://onlinelibrary.wiley.com/doi/10.1111/cid.13186 by CochraneItalia, Wiley Online Library on [15/04/2024]. See the Terms and Conditions (https://onlinelibrary.wiley.com/terms-and-conditions) on Wiley Online Library for rules of use; OA articles are governed by the applicable Creative Commons License

34. Aimetti M, Ferrarotti F, Mariani GM, Ghelardoni C, Romano F. Soft tissue and crestal bone changes around implants with platform-switched abutments placed nonsubmerged at subcrestal position: a 2-year clinical and radiographic evaluation. *Int J Oral Maxillofac Implants*. 2015;30(6):1369-1377.
35. Koutouzis T, Neiva R, Nonhoff J, Lundgren T. Placement of implants with platform-switched Morse taper connections with the implant-abutment interface at different levels in relation to the alveolar crest: a short-term (1-year) randomized prospective controlled clinical trial. *Int J Oral Maxillofac Implants*. 2013;28(6):1553-1563.
36. Lombardi T, Berton F, Salgarello S, et al. Factors influencing early marginal bone loss around dental implants positioned subcrestally: a multicenter prospective clinical study. *J Clin Med*. 2019;8(8):1168.
37. Pellicer-Chover H, Penarrocha-Diago M, Penarrocha-Oltra D, Gomar-Vercher S, Agustin-Panadero R, Penarrocha-Diago M. Impact of crestal and subcrestal implant placement in periimplant bone: a prospective comparative study. *Med Oral Patol Oral Cir Bucal*. 2016; 21(1):e103-e110.
38. Al Amri MD, Al-Johany SS, Al Baker AM, Al Rifaiy MQ, Abduljabbar TS, Al-Kheraif AA. Soft tissue changes and crestal bone loss around platform-switched implants placed at crestal and subcrestal levels: 36-month results from a prospective split-mouth clinical trial. *Clin Oral Implants Res*. 2016;28(11):1342-1347.
39. Gatti C, Gatti F, Silvestri M, et al. A prospective multicenter study on radiographic crestal bone changes around dental implants placed at crestal or subcrestal level: one-year findings. *Int J Oral Maxillofac Implants*. 2018;33(4):913-918.
40. Valles C, Rodríguez-Ciurana X, Clementini M, Baglivo M, Paniagua B, Nart J. Influence of subcrestal implant placement compared with equicrestal position on the peri-implant hard and soft tissues around platform-switched implants: a systematic review and meta-analysis. *Clin Oral Investig*. 2018;22(2):555-570.
41. Kennedy E. *Partial denture construction*. Dental Items of Interest; 1928:3-8.
42. Hwang D, Wang HL. Medical contraindications to implant therapy. Part I: absolute contraindications. *Implant Dent*. 2006;15(4): 353-360.
43. Sentineri R, Lombardi T, Berton F, Stacchi C. Laurell-Gottlow suture modified by Sentineri for tight closure of a wound with a single line of sutures. *Br J Oral Maxillofac Surg*. 2016;54(1):e18-e19.
44. Gomez-Roman G, Launer S. Peri-implant bone changes in immediate and non-immediate root-analog stepped implants-a matched comparative prospective study up to 10 years. *Int J Implant Dent*. 2016; 2(1):15.
45. Linkevicius T, Puisys A, Steigmann M, Vindasiute E, Linkeviciene L. Influence of vertical soft tissue thickness on crestal bone changes around implants with platform switching: a comparative clinical study. *Clin Implant Dent Relat Res*. 2015;17(6):1228-1236.
46. Ramanauskaite A, Schwarz F, Sader R. Influence of width of keratinized tissue on the prevalence of peri-implant diseases: a systematic review and meta-analysis. *Clin Oral Implants Res*. 2022;33(1):8-31.
47. Sanz M, Schwarz F, Herrera D, et al. Importance of keratinized mucosa around dental implants: consensus report of group 1 of the DGI/SEPA/osteology workshop. *Clin Oral Implants Res*. 2022;33-(Suppl 23):47-55.
48. Trisi P, Berardini M, Falco A, Podaliri Vulpiani M, Perfetti G. Insufficient irrigation induces peri-implant bone resorption: an in vivo histologic analysis in sheep. *Clin Oral Implants Res*. 2014;25(6):696-701.
49. Barone A, Alfonsi F, Derchi G, et al. The effect of insertion torque on the clinical outcome of single implants: a randomized clinical trial. *Clin Implant Dent Relat Res*. 2016;18(3):588-600.
50. Caricasulo R, Malchiodi L, Ghensi P, Fantozzi G, Cucchi A. The influence of implant-abutment connection to peri-implant bone loss: a systematic review and meta-analysis. *Clin Implant Dent Relat Res*. 2018;20(4):653-664.
51. Wilson TG Jr. The positive relationship between excess cement and peri-implant disease: a prospective clinical endoscopic study. *J Periodontol*. 2009;80(9):1388-1392.
52. Gehrke P, Bleuel K, Fischer C, Sader R. Influence of margin location and luting material on the amount of undetected cement excess on CAD/CAM implant abutments and cement-retained zirconia crowns: an in-vitro study. *BMC Oral Health*. 2019;19(1):111.
53. Koutouzis T, Neiva R, Nair M, Nonhoff J, Lundgren T. Cone beam computed tomographic evaluation of implants with platform-switched Morse taper connection with the implant-abutment interface at different levels in relation to the alveolar crest. *Int J Oral Maxillofac Implants*. 2014;29(5):1157-1163.
54. Froum SJ, Cho SC, Suzuki T, Yu P, Corby P, Khouly I. Epicrestal and subcrestal placement of platform-switched implants: 18 month-result of a randomized, controlled, split-mouth, prospective clinical trial. *Clin Oral Implants Res*. 2018;29(4):353-366.
55. Ogino Y, Matsushita Y, Sasaki M, Ayukawa Y, Koyano K. A 3-year prospective study on radiographic marginal bone evaluation around platform-shifting implants with internal conical connections. *Int J Oral Maxillofac Implants*. 2021;36(3):574-580.
56. Wang SH, Ko YC, Tsai MT, et al. Can male patient's age affect the cortical bone thickness of jawbone for dental implant placement? A cohort study. *Int J Environ Res Public Health*. 2021;18(8):4284.
57. Sotto-Maior BS, de Andrade LC, Mendes Senna P, de Villa CG, Del Bel Cury AA. Biomechanical evaluation of subcrestal dental implants with different bone anchorages. *Braz Oral Res*. 2014;28: S1806-83242014000100235.
58. Reddy MS, Rajasekar S, Eid Abdelmagyd HA. Evaluating the effect of subcrestal placement on platform switched short dental implants and von mises stress in D3 bone-a 3D FEM study. *Niger J Clin Pract*. 2021;24(5):660-666.
59. Ellendula Y, Chandra Sekar A, Nalla S, Basany RB, Sailasri K, Thandu A. Biomechanical evaluation of stress distribution in equicrestal and sub-crestally placed, platform-switched Morse taper dental implants in D3 bone: finite element analysis. *Cureus*. 2022;14(4): e24591.
60. Everts V, Delaisse JM, Korper W, et al. The bone lining cell: its role in cleaning Howship's lacunae and initiating bone formation. *J Bone Miner Res*. 2002;17(1):77-90.
61. Jahani M, Genever PG, Patton RJ, Ahwal F, Fagan MJ. The effect of osteocyte apoptosis on signalling in the osteocyte and bone lining cell network: a computer simulation. *J Biomech*. 2012;45(16):2876-2883.
62. Adachi T, Aonuma Y, Taira K, Hojo M, Kamioka H. Asymmetric intercellular communication between bone cells: propagation of the calcium signaling. *Biochem Biophys Res Commun*. 2009;389(3):495-500.
63. Simons WF, De Smit M, Duyck J, Coucke W, Quirynen M. The proportion of cancellous bone as predictive factor for early marginal bone loss around implants in the posterior part of the mandible. *Clin Oral Implants Res*. 2015;26(9):1051-1059.
64. Insua A, Monje A, Wang HL, Miron RJ. Basis of bone metabolism around dental implants during osseointegration and peri-implant bone loss. *J Biomed Mater Res A*. 2017;105(7):2075-2089.
65. Katafuchi M, Weinstein BF, Leroux BG, Chen YW, Daubert DM. Restoration contour is a risk indicator for peri-implantitis: a cross-sectional radiographic analysis. *J Clin Periodontol*. 2018;45(2): 225-232.
66. Soulami S, Slot DE, van der Weijden F. Implant-abutment emergence angle and profile in relation to peri-implantitis: a systematic review. *Clin Exp Dent Res*. 2022;8(4):795-806.
67. Lops D, Romeo E, Stocchero M, Palazzolo A, Manfredi B, Sbricoli L. Marginal bone maintenance and different prosthetic emergence angles: a 3-year retrospective study. *J Clin Med*. 2022;11(7):2014.
68. Strauss FJ, Siegenthaler M, Hämmerle CHF, Sailer I, Jung RE, Thoma DS. Restorative angle of zirconia restorations cemented on non-original titanium bases influences the initial marginal bone loss:

17088208, 2023, 2, Downloaded from https://onlinelibrary.wiley.com/doi/10.1111/cid.13186 by CochraneItalia, Wiley Online Library on [15/04/2024]. See the Terms and Conditions (https://onlinelibrary.wiley.com/terms-and-conditions) on Wiley Online Library for rules of use; OA articles are governed by the applicable Creative Commons License

5-year results of a prospective cohort study. *Clin Oral Implants Res*. 2022;33(7):745-756.
69. Ercoli C, Jammal G, Buyers M, et al. Influence of apico-coronal implant placement on post-surgical crestal bone loss in humans. *J Periodontol*. 2017;88(8):762-770.
70. Discepoli N, Mirra R, Vesentin C, Marruganti C, Ferrari M. Artificial biofilm removal in a peri-implant mucositis model: efficacy of air polishing technology as adjunct to ultrasonic debridement alone and impact of the site and the depth of mucosal tunnel - an in vitro study. *Clin Implant Dent Relat Res*. 2022;24(2):242-250.
71. Chan D, Pelekos G, Ho D, Cortellini P, Tonetti MS. The depth of the implant mucosal tunnel modifies the development and resolution of experimental peri-implant mucositis: a case-control study. *J Clin Periodontol*. 2019;46(2):248-255.
72. Heitz-Mayfield LJA, Huynh-Ba G. History of treated periodontitis and smoking as risks for implant therapy. *Int J Oral Maxillofac Implants*. 2009;24(Suppl):39-68.
73. Ibañez C, Catena A, Galindo-Moreno P, Noguerol B, Magán-Fernández A, Mesa F. Relationship between long-term marginal bone loss and bone quality, implant width, and surface. *Int J Oral Maxillofac Implants*. 2016;31(2):398-405.
74. Makary C, Menhall A, Zammarie C, et al. Primary stability optimization by using fixtures with different thread depth according to bone density: a clinical prospective study on early loaded implants. *Materials (Basel)*. 2019;12(15):2398.

How to cite this article: Stacchi C, Lamazza L, Rapani A, et al. Marginal bone changes around platform-switched conical connection implants placed 1 or 2 mm subcrestally: A multicenter crossover randomized controlled trial. *Clin Implant Dent Relat Res*. 2023;25(2):398-408. doi:10.1111/cid.13186

17088208, 2023, 2, Downloaded from https://onlinelibrary.wiley.com/doi/10.1111/cid.13186 by CochraneItalia, Wiley Online Library on [15/04/2024]. See the Terms and Conditions (https://onlinelibrary.wiley.com/terms-and-conditions) on Wiley Online Library for rules of use; OA articles are governed by the applicable Creative Commons License